

## Reincident corneal epithelial inclusion cyst in a dog: a case report

E.M. MARTIN-SUAREZ, A. GALAN, J.M. MOLLEDA

Faculty of Veterinary, University of Cordoba, Cordoba, Spain

**ABSTRACT:** An unilateral corneal epithelial inclusion cyst (CEIC) in a 8-years-old female mixed Poodle is reported. The cyst had been observed for 60 days, was unique, not congenital and only one eye was involved. One year prior to the referral the dog was treated with antibiotics due to an ocular trauma caused by a fight with a cat. In the same eye, palpebral melanocytic tumor and corneal dystrophy were also observed. In order to remove the CEIC a superficial keratectomy was performed. Collagen contact lens and topical antibiotics were the medical treatment of choice. Fifteen month after surgery the dog was referred for recurrence of the CEIC. A second keratectomy and similar topical treatment was attempted again. A second recurrence 16 months after surgery has not been observed to the date. Cytology and histology analysis of the cyst confirmed the diagnosis of the CEIC. Microbiologic studies were also realized and *Staphylococcus epidermidis* was aisled twice in fifteen months. In this case a relapsing CEIC is reported associated to *S. epidermidis* contamination. Corneal dystrophy and palpebral melanoma were concomitant lesions, although no relations with the CEIC were concluded.

**Keywords:** corneal epithelial inclusion cyst; corneal disease; dog

Corneal epithelial inclusion cyst (CEIC) involving any of the four layers of the cornea has been reported in human and dog (Whitley and Gilger, 1999; Campos et al., 2002). In dogs is a rare condition and 21 cases have been reported in the veterinary bibliography (Campos et al., 2002). Epithelial cells incarceration in the stroma, resulting in cyst changes and accumulation of desquamated cell, has been supposed as possible cause (Bedford, 1997; Cullen and Grahn, 2001; Campos et al., 2002). The aetiology remains uncertain and corneal trauma or ulcer before the cyst formation has not could be concluded (Campos et al., 2002). However, most documented cases of CEIC in dogs reveals that surgical trauma or accidental corneal injuries could be the inciting factors (Koch et al., 1974; Schmidt and Prasse, 1976; Bedford et al., 1990).

### Case report

An 8-years-old female mixed Poodle was referred for a white, elevated and unpainful corneal lesion

at the Ophthalmology Service of the University of Cordoba. Due to a fight with a cat, an ocular trauma history one year prior to presentation at the Hospital was reported by the owners. The dog was treated with antibiotic and atropine and recovered uneventfully. The owners reported an evolution of sixty days and no sings of discomfort. At the moment of examination, the dog presented a white and elevated mass, which was localized on the superotemporal quadrant of the left cornea. It was six millimetres of diameter and three high (Figure 1). Clinical examination revealed perilesional oedema and vascularisation on and around the cyst. No conjunctival congestion, ocular discharge, discomfort or visual deficits were observed. Slit lamp examination of the cyst showed involvement of the epithelium and upper stroma. A bilateral and symmetric corneal dystrophy affecting corneal stroma was also observed centrally. Schirmer tear test (STT) values were 19 and 17 mm in the left and right eye respectively. Intraocular pressure (IP) was 16–17 mm Hg in the left and right eye, respectively. The fluorescein dye test was negative. Indirect

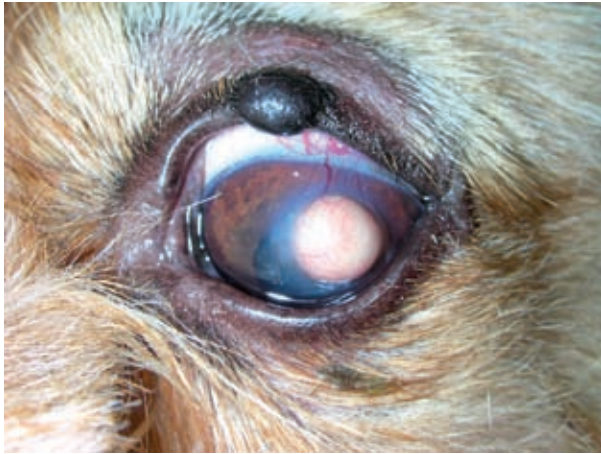

Figure 1. Palpebral melanocytoma and corneal epithelial inclusion cyst at the initial presentation. A corneal cyst, of 6 mm of diameter, was localized on the superotemporal quadrant. Perilesional oedema, fibroplasia and vascularisation on and around the cyst were noted

ophthalmoscopy revealed no abnormal findings on either fundus. Presumptive clinical diagnosis was corneal epithelial inclusion cyst (CEIC). In the same eye, a palpebral pigmented mass of five millimetres in size was also observed by the owners since five months and presumptive diagnosis

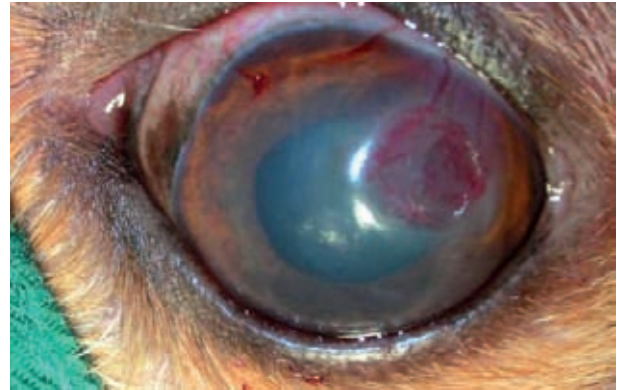


Figure 2. After keratectomy was performed, a collagen lens was employed to improve the epithelisation of the cornea injury

of melanocytic tumor was realized. At the time of examination, the dog was alert and otherwise in apparent good health. A complete blood count and chemistry did not show any abnormal changes, and cholesterol, tryglicerides, calcium and glucose values were within normal limits.

Surgical excision of the presumptive neoplasm and CEIC was recommended. CIEC was excised by keratectomy (Figure 2) and submitted for cytology. The cyst was inadvertently ruptured prior to

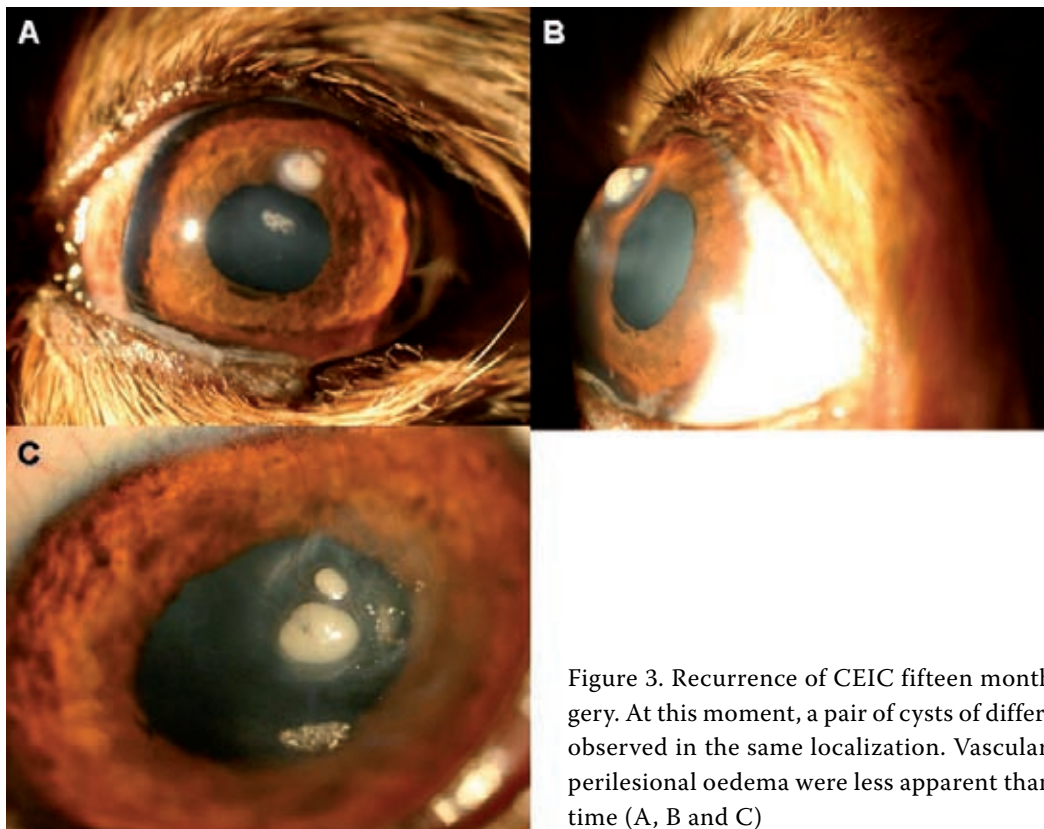


Figure 3. Recurrence of CEIC fifteen months after surgery. At this moment, a pair of cysts of different size was observed in the same localization. Vascularization and perilesional oedema were less apparent than in the first time (A, B and C)

complete removal. Sterile swab was applied over the ulcer and submitted to microbiological study. Cytological findings showed intact and degenerated epithelial cells and diagnosis of CEIC was confirmed. *S. epidermidis* was aisled by microbiological exam of the lumen of the cyst. Non histological studies could be attempted. Topical atropine 1% two times per day during three days (Atropina 1%, Alcon Cusi) and chloranphenicol four times per day during 14 days (Cloranfenicol, Alcon Cusi) were applied postsurgically. A collagen lens (Proshield, Alcon) was employed to improve the re-epithelization. Palpebral neoplasm was removed by full-thickness "V" excision (Bedford, 1999) without complications and melanocytoma was confirmed by histological studies. No medical or surgical treatment was realized for corneal dystrophy.

Fifteen months after surgery, the dog presented again for consultation due to recurrence of the CIEC. At this time, pair of cysts of different size was observed in the same localization. Vascularization and perilesional oedema were less apparent than in the first time but the same corneal vessels were filled. Corneal dystrophy showed a more advanced state with more dense opacities and nebular-type oval corneal opacity appearance (Figure 3). A new keratectomy was performed to eliminate the cysts and microbiological and histological studies were performed. Histological studies revealed a cyst mass including into the epithelium and superficial stroma. The mass was covered by hyperplastic corneal epithelium with a few small vessels over the stroma. Microbiological analyses concluded

*S. epidermidis* as unique pathogenic agent involved. Topical ciprofloxacin (Oftacilox, Alcon Cusi) at 1 drop, q6h, during 14 days was the choice treatment after surgery. Sixteen months after second keratectomy no recurrence of the CEIC has been observed (Figure 4).

## DISCUSSION

In human, CEIC may develop as a complication of corneal ulcer, penetrating trauma or intraocular surgery (Haller et al., 2002). Keratotomies, epikeratoplasties and corneal epithelium dystrophies with recurrent erosion have been proposed as cause of this disease (Campos et al., 2002), although congenital origin has also been described (Haller et al., 2002). In dogs, it is a rare corneal condition and the cause has not been definitively determined. Like in humans, CIEC could be congenital (Bedford et al., 1990), however traumatic origin could be also conferred, due to the most dog present a history of previous corneal ulceration or lesion (Bedford et al., 1990; Whitley and Gilger, 1999; Campos et al., 2002). Corneal indolent ulcer and keratectomies have been also hypothesized as possible origins in dog (Campos et al., 2002). It has been supposed the inciting trauma introduces corneal epithelial cells into the superficial corneal stroma. During repair, these cells proliferate within the stroma with consequent retaining of secretions and desquamated material (Bedford et al., 1990; Cullen and Grahn, 2001). Biopsy studies reported in human have demonstrated retention of epithelium within the incision wound of radial keratectomy and adjacent abnormal keratocytes with degenerative changes (Jester et al., 1983).

There is not know breed predisposition to epithelial inclusion cyst formation (Cullen and Grahn, 2001). CIEC may vary in size and corneal position and result in varying amounts of lagophthalmos and vision impairment (Bedford et al., 1990). It appears as raised, white to pink o yellowish corneal mass. This corneal disease is considered a benign unilateral entity, although visual capability could be impaired as consequence to its size and corneal position. The differential diagnosis included corneal neoplasm, abscess, poorly pigmented dermoid, bullous keratopathy, and iris prolapse following corneal perforation. All these pathologies show clinical differences, corneal abscess cause discomfort and uveitis and normally these are not raised lesions,

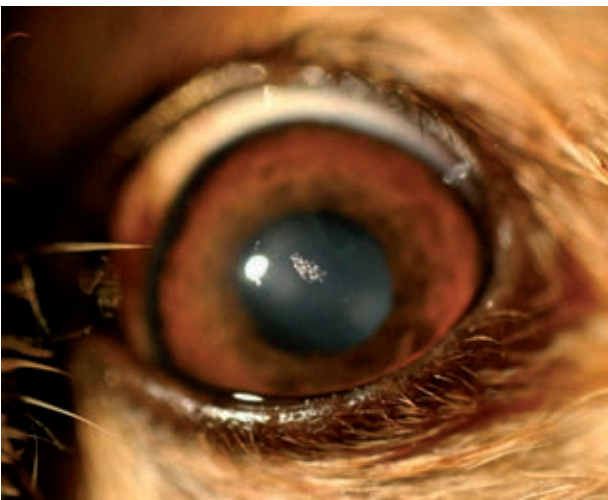


Figure 4. Aspect of the eye sixteen months after second keratectomy. No recurrence of the CEIC has been observed to the date

bullous keratopathy cause edema and discomfort, dermoids are congenital and haired, and iris prolapse cause pain, uveitis and dyscoria (Bedford et al., 1990; Campos et al., 2002). Primary corneal neoplasia should be considered in the differential diagnosis of corneal masses (Bernays et al., 1999). So, papilloma, histiocytoma, fibrous histiocytoma and nodular fasciitis may have been the most important differential diagnosis in this case, however these more vascularized masses are usually localized at the temporal cornea, involving the corneoscleral limbus. In this case, a tentative clinical diagnosis of CEIC was considered because of the previous ocular trauma and the visual similarity to previous reported cases (Bedford et al., 1990; Bedford, 1997; Cullen and Grahn, 2001; Campos et al., 2002).

No previous relation has been described with other ocular diseases. Mechanical factors that caused chronic changes in the cornea may have been causative factors for induction of primary dysplastic or neoplastic changes (Bernays et al., 1999). A relation could be suspected between melanocytoma of the meibomian glands and CEIC. However, this affirmation may be not very feasible due to the palpebral tumours are a common entity in dogs and not previous relation have been described with CEIC formation. On the other hand, a relation with central corneal dystrophy may be also thought, although coincidence in localization into the cornea was neither seen.

In the previous cases reports no neutrophils or microorganisms were seen by histological studies (Termote, 2006). Therefore, pathogenic agents have not been previously described in association with CEIC. *S. epidermidis* is a saprophytic agent with moderate aggressive capability and ability to grow anaerobically. This agent has been aisled over the ocular surface as normal flora of man and dog (Murphy et al., 1978; Samuelson et al., 1984; Gerding et al., 1988). In a prospective clinical study in humans the most commonly isolated bacteria in post-traumatic keratitis was *S. epidermidis* (Steffan and Neciu, 2006). In this case, *S. epidermidis* was aisled as unique pathogenic agent; however clinical sings of corneal abscess (clinical appearance, absence of uveitis and ocular pain or discomfort) were not present. A contamination of the swab during the surgery has to be considered. However, an invasion of the germen and keratinocytes within the stroma and subsequent proliferation of these cells could be more feasible due to the germen was aisled for two times.

Treatment of CEIC in man has included aspiration, cauterization, and excision of the anterior wall in order to prevent astigmatism (Mifflin et al., 2001; Haller et al., 2002). Because astigmatism is not of primary concern in the dog, keratectomy is the treatment of choice (Cullen and Grahn, 2001; Campos et al., 2002). Because of the superficial corneal stromal involvement, conjuntival or corneal grafts are not usually employed (Cullen and Grahn, 2001). Topical antibiotics to prevent contamination and conjuntival graft after keratectomy have been also suggested. No references of collagen lens use after keratectomy of CEIC have been found in the veterinary literature. Recurrence of the CEIC is not expected (Whitley and Gilger, 1999), however in this case two smaller CEIC appeared 15 months after first keratectomy. The most likely explanation could be an incomplete and inadequate surgical excision of the original cyst. Perhaps, collagen lens may predispose to recurrence of this entity increasing the re-epithelization. The increased of velocity of epithelization may cause keratocytes and microorganism proliferate within the stroma, however any of these hypothesis can be concluded.

## REFERENCES

- Bedford P.G.C. (1997): What is your diagnosis? A corneal epithelial inclusion cyst. *Journal of Small Animal Practice*, 38, 140–171.
- Bedford P.G.C. (1999): Diseases and surgery of the canine eyelid. In: Gelat K.N. (ed.): *Veterinary Ophthalmology*. 2<sup>nd</sup> ed. Lippincott Williams & Wilkins, Maryland. 538–568.
- Bedford P.G.C., Grierson I., Mckechnie N.M. (1990): Corneal epithelial inclusion cyst in the dog. *Journal of Small Animal Practice*, 31, 64–68.
- Bernays M.E., Flemming E., Peiffer L.R. Jr. (1999): Primary corneal papilloma and squamous cell carcinoma associated with pigmentary keratitis in four dogs. *Journal of American Veterinary Medical Association*, 214, 215–217.
- Campos C.F., Talieri I.C., Mendes F.A., Laus J.L. (2002): Corneal epithelial inclusion cyst in a dog. *Sciencia Rural*, 32, 521–523.
- Cullen C.L., Grahn B.H. (2001): Diagnostic ophthalmology. Epithelial inclusion cyst of the right cornea. *Canadian Veterinary Journal*, 42, 230–231.
- Gerding P.A., McLaughling S.A., Troop M.W. (1988): Pathogenic bacteria and fungi associated with external ocular diseases in dogs: 131 cases (1981–1986). *Jour-*

- nal of American Veterinary Medical Association, 193, 242–244.
- Haller J.A., Walter J.S., Thomsen R.W., Gottss J.D. (2002): Surgical approaches to the management of epithelial cysts. *Transactions of the American Ophthalmological Society*, 100, 79–83.
- Koch S.A., Langloss J.M., Schmidt G. (1974): Corneal epithelial inclusion cyst in four dogs. *Journal of American Veterinary Medical Association*, 164, 1190–1191.
- Jester J.V., Villasenor R.A., Miyashiro J. (1983): Epithelial inclusion cyst following radial keratectomy. *Archives of Ophthalmology*, 101, 611–615.
- Mifflin M.D., Byers T.L., Elliot R., Hoffman R. (2001): Surgical treatment of intralesional epithelial corneal cyst. *Cornea*, 20, 222–225.
- Murphy J.M., Lavach J.D., Severin G.A. (1978): Survey of conjunctival flora in dogs with clinical sings of external eye disease. *Journal of American Veterinary Medical Association*, 172, 66–68.
- Samuelson D.A., Andersen T.L., Gwin R.M. (1984): Conjunctival fungal flora in horses, cattle, dogs, and cats. *Journal of American Veterinary Medical Association*, 184, 1240–1243.
- Schmidt G., Prasse K.W. (1976): Corneal epithelial inclusion cyst associated with keratectomy in a dog. *Journal of American veterinary medical Association*, 168, 144.
- Steffan C., Neciu A. (2006): Post-traumatic bacterial keratitis – a microbiological prospective clinical study. *Oftalmologia*, 50, 118–122.
- Termote S. (2006): Pet-vision. *Ophthalmology Referral Practice. Newsletter*. [www.pet-vision.co.uk](http://www.pet-vision.co.uk)
- Whitley R.D., Gilger B.C. (1999): Disease of the canine cornea and sclera. In: Gelat K.N. (ed.): *Veterinary Ophthalmology*. 2<sup>nd</sup> ed. Lippincott Williams & Wilkins, Maryland. 635–673.

Received: 2008–06–25

Accepted after corrections: 2009–02–18

---

Corresponding Author:

Alba Galan Rodriguez, Campus Universitario de Rabanales, Crrta Madrid km 396, CP 14004, Department of Small Animal Medicine and Surgery, University of Cordoba, Spain  
Tel. + 34 957 212 011, E-mail: [pv2garoa@uco.es](mailto:pv2garoa@uco.es)

---