

Effects of pelvis rotation on the projected radiographic position of the femoral head in relationship to the acetabulum

J. MARTINS^{1*}, B. COLAÇO^{1,2}, S. ALVES-PIMENTA^{1,2}, A. FERREIRA³, M. GINJA^{1,4}

¹Centre for Research and Technology of Agro-Environmental and Biological Sciences, University of Trás-os-Montes e Alto Douro, Vila Real, Portugal

²Department of Animal Science; University of Trás-os-Montes e Alto Douro, Vila Real, Portugal

³Faculty of Veterinary Medicine, University of Lisbon, Lisbon, Portugal

⁴Department of Veterinary Science, University of Trás-os-Montes e Alto Douro, Vila Real, Portugal

*Corresponding author: ccarlamartins@sapo.pt

ABSTRACT: The aim of this study was to describe the influence of pelvis rotation on the projected radiographic position of the femoral head in relationship to the acetabulum in the standard ventrodorsal hip extended view, i.e. Norberg angle, pelvic thickness at the level of the cranial effective acetabular rim, femoral head subluxation index, femoral head subluxation category and femoral head-acetabular distance. Twelve adult dogs of large and giant breeds were radiographed in standard hip extended view and with 2°, 4° and 6° of rotation on the right and left sides. Norberg angle, pelvic thickness, subluxation index, subluxation category and femoral head-acetabular distance were measured on radiographs and analysed comparing a normal position with positions of different degrees of rotation for the dependent and non-dependent side. All the studied parameters showed adequate repeatability. Norberg angle and femoral head-acetabular distance did not show significant mean differences in all degrees of rotated pelvis ($P > 0.05$). The pelvic thickness showed an increase with the degree of rotation on the dependent side ($P < 0.05$) and a slight decrease on the non-dependent side ($P > 0.05$). The subluxation index and subluxation category showed an increase with the degree of rotation on the dependent side and a decrease on the non-dependent side ($P < 0.05$). As the subluxation index and subluxation category are parameters used in the classification of the main international hip dysplasia scoring systems, pelvic rotation can impair the final hip score, especially in scoring systems that are based on the worst joint.

Keywords: dog; femoral head-acetabular distance; Norberg angle; pelvic thickness; subluxation categories; subluxation index

Hip dysplasia (HD) is the most important debilitating orthopaedic disease in large- and giant-breed dogs (Lust et al. 2001; Thompson et al. 2007; Dennis 2012; Smith et al. 2012) and is one of the main areas of interest in veterinary orthopaedics (Martins et al. 2012). HD is a polygenic and heritable condition dominated by a major gene (Thompson et al. 2007; Dennis 2012); however, environmental factors influence the phenotypic expression and the severity of the disorder in affected individuals (Thompson et al. 2007; Chalmers et al. 2013). Despite inten-

sive research worldwide, a marker-assisted accurate canine HD diagnosis test is still lacking (Ginja et al. 2015). HD is characterised by subluxation of the femoral heads and joint laxity (Lust et al. 2001; Gold et al. 2009), which often leads to secondary debilitating osteoarthritis, with consequent pain and reduction in joint function (Adams et al. 2000; Tomlinson and Johnson 2000; Lust et al. 2001; Ohlerth et al. 2001; Culp et al. 2006; Thompson et al. 2007; Ginja et al. 2009). Radiography remains the established imaging technique for HD diagnosis

(Andronescu et al. 2015; Ginja et al. 2015) and is the only accepted tool in large-scale screening of dogs for HD, even though it does not accurately reflect the desired genetic pool (Fluckiger et al. 1999). As part of attempts to control canine HD and reduce its incidence, several radiographic screening programs have been developed worldwide (Dennis 2012). The main canine HD scoring systems using the standard ventrodorsal hip extended (VDHE) view are those of the Fédération Cynologique Internationale (FCI), the Orthopedic Foundation for Animals (OFA) and the British Veterinary Association and the Kennel Club (BVA/KC) (Genevois et al. 2007; Verhoeven et al. 2007; Comhaire et al. 2009; Ginja et al. 2009). The relationship between the acetabular and femoral head has great importance in these radiographic screening programs (Thompson et al. 2007). The dorsal acetabular edge (DAE) and the cranial effective acetabular rim (CAR) are two important structures during the analysis of acetabular morphology. Changes in the radiographic projection of DAE and CAR may affect the assessment of femoral head coverage and other relationships with the acetabulum (Thompson et al. 2007; Dennis 2012). The correct positioning of the dog is of uppermost importance for an adequate radiographic interpretation (Genevois et al. 2007). Some canine HD scoring systems have been considered to be subjective and attempts to improve them have included the introduction of quantifiable evaluation parameters (Fluckiger 1995; Dennis 2012; Smith et al. 2012). The Norberg angle (NA) measurement is currently one of the main parameters used in the FCI and BVA/KC systems, in order to evaluate hip-joint laxity and the severity of any subluxation and depth of acetabulum (Ginja et al. 2010; Dennis 2012). According to a study (Genevois et al. 2007), pelvic rotation along the body axis is the most common malposition reported in standard VDHE view (29.8%). It has been postulated that pelvic rotation along the long body axis induces a decrease in DAE femoral head coverage and on the NA in the ipsilateral side of the rotation, and an increase on the contralateral side (Genevois et al. 2007; Thompson et al. 2007). We are not aware of any studies that report objective quantification of the effect of pelvic rotation along the longitudinal body axis on the projected radiographic position of the femoral head in relationship to the acetabulum on the VDHE view. In this study, we selected quantifiable acetabular and/or femoral radiographic parameters directly or indirectly as-

sociated with canine HD scoring: the NA, pelvic thickness at the level of the cranial effective acetabular rim (PT), femoral head subluxation index (SI), femoral head subluxation categories (SC) and the femoral head-acetabular distance (FAD). The main purpose of the present study was to investigate the relationship between the value of these hip parameters in the standard VDHE view and in a modified VDHE view with 2°, 4° and 6° of rotation on the right and left sides. We hypothesised that pelvic rotation changes the values of these hip parameters (NA, PT, SI, SC and FAD) to different extents on the dependent and non-dependent rotation sides.

MATERIAL AND METHODS

The radiographic study was performed on 12 adult cadaver specimens from large- and giant-dog breeds. Cadavers had been frozen at -20 °C for less than one month, and were thawed at room temperature for 2–3 days before the radiographic study. No gender or breed criteria were used. The weights ranged from 20 to 45 kg (32.2 ± 7.8 kg) and were evaluated at the Veterinary Teaching Hospital of the University of Trás-os-Montes e Alto Douro. The cadavers were positioned and immobilised on an X-ray table in the standard VDHE view using a special holder device and pins applied to each femoral diaphysis and fixed in a transverse strip of wood, as described in a previous study (Martins et al. 2016). The first radiographic view of the pelvis was performed to evaluate the technical quality of the positioning and used as a reference, once acceptable positioning was achieved, i.e. symmetry of pelvis, femurs parallel to each other and patella over the midline of the femurs (Ginja et al. 2010). In each animal, six more VDHE views with pelvis rotation along the long axis of 2°, 4° and 6° on the right and left sides were obtained. These grades of rotation were achieved by raising the special cadaver holder device on the right or left side with three firm wedges of different thicknesses; evaluation was carried out using a manual inclinometer (Figure 1) as described in a previous study (Martins et al. 2016). Only normal hips or those with slight signs of HD (based on the FCI scheme) were included in the study, and all included hips allowed an unequivocal identification of essential radiographic landmarks. The measurements were performed using computer software (OSIRIS Imaging Software® ver-

doi: 10.17221/127/2016-VETMED

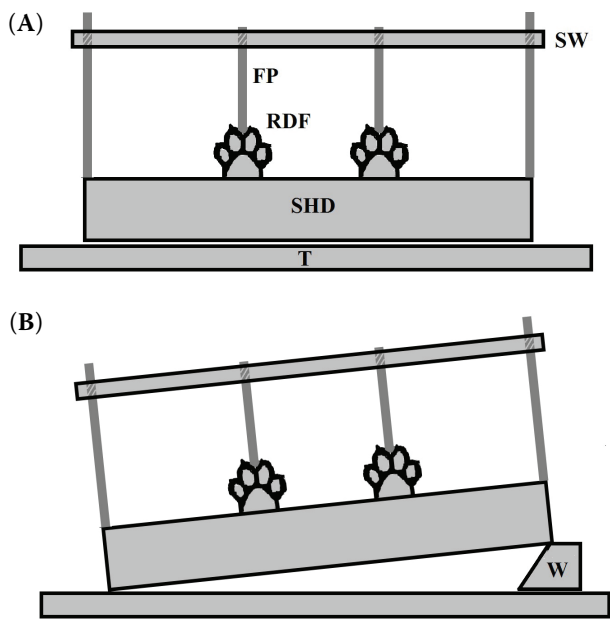


Figure 1. Illustration outlining the rear view of the special holder device. (A) Cadaver positioned in the ventrodorsal hip extended view. (B) Modified view with pelvic rotation of 6° to the right side (elevating the left side), making the right hip dependent and the left non-dependent
 FP = femoral pin, RDF = right dog foot, SHD = special holder device, SW = strip of wood, T = X-ray table, W = wedge

sion 3.1: University Hospital of Geneva, Geneva, Switzerland) in digital radiographs, at a resolution of 300 dpi. All measurements were performed by the same examiner, an experienced radiologist (MMDG). First, in the normal hip extended view pelvis symmetry was evaluated; the iliac horizontal diameter (IHD) was measured by drawing a straight line between the dorsal and ventral iliac spines at the level of the cranial aspect of the sacroiliac joint (Martins et al. 2016); then, in two independent sessions measurements of NA, PT, SI, SC and FAD in the left and right sides were performed to evaluate repeatability; finally, in six more sessions these variables were measured for each degree of rotation (series of 2°, 4° and 6° of rotation for right and left side). The NA was determined in degrees as the angle formed by a line joining the centre of the femoral heads and a line joining the centre of the femoral head and the craniolateral aspect of the ipsilateral acetabular rim (Figure 2) (Vandekerckhove et al. 2003; Ginja et al. 2008; Comhaire et al. 2009; Bausman and Wendelburg 2010). The centre of the femoral head was obtained using a circular calliper to delimitate the circular components of the femo-

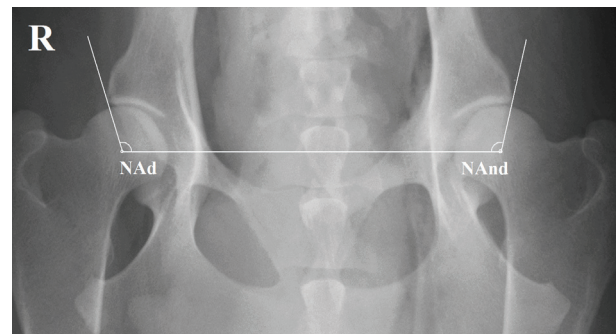


Figure 2. Ventrodorsal hip extended view with pelvic rotation of 6° to the right side. The Norberg angle (NA) was determined as the angle formed by a line joining the centre of the femoral heads and a line joining the centre of the femoral head and the craniolateral aspect of the ipsilateral acetabular rim
 NAd = Norberg angle dependent side, NAnd = Norberg angle non-dependent side, R = right side

ral head (proximal and medial aspects) and then its geometric centre was determined (Ginja et al. 2006). The PT was measured in millimetres as the thickness of the pelvis at the level of the cranial ef-

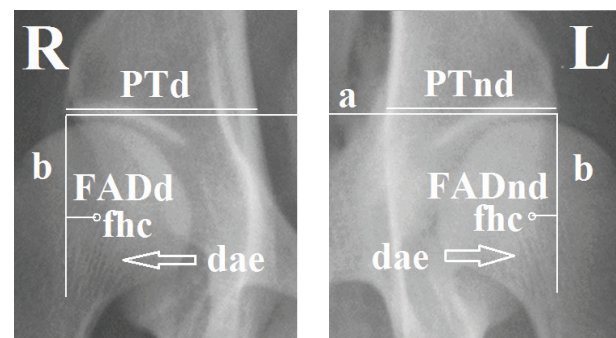


Figure 3. Magnification of right (R) and left (L) hip joints from Figure 2. Pelvic thickness (PT) denotes the thickness of the pelvis at the level of the cranial effective acetabular rim on the dependent (PTd) and non-dependent (PTnd) sides. The femoral head subluxation category was determined by attending to the position of the femoral head centre (fhc) relative to the dorsal acetabular edge (dae) and taking into account the congruency of the fit between the femoral head and the cranial acetabular edge. Femoral head-acetabular distance (FAD) was determined by drawing a line between both cranial effective acetabular rims (a), and then a second perpendicular line from the lateral aspect of the cranial effective acetabular rim (b). FAD was measured as the minimum horizontal distance between the second perpendicular line and the centre of the femoral head on the dependent (FADd) and non-dependent (FADnd) sides

fective acetabular rim (Figure 3). The SI was measured in millimetres as the linear distance between the centre of the femoral head and the acetabular centre, divided by the radius of the femoral head (Figure 4) (Fluckiger et al. 1999). The centre of the acetabulum was obtained using a circular calliper to draw a circle contacting the cranial and caudal acetabular edges and then its geometric centre was determined. The degree of subluxation (SC) was assessed in seven categories: 0 – femoral head centred in acetabulum; 1 – femoral head centre (FHC) medial to the DAE; 2 – FHC superimposed on the DAE; 3 – FHC lies just lateral to the DAE; 4 – FHC is clearly lateral to the DAE; 5 – FHC is well lateral to the DAE; 6 – FHC completely dislocated from acetabulum (Figure 2) (Dennis 2012). The FAD was measured in millimetres and determined by drawing a line between both cranial effective acetabular rims; then, a second perpendicular line was drawn from the lateral aspect of the cranial acetabular rim and the FAD was measured as the minimum horizontal distance between the second perpendicular line and the centre of the femoral head (Figure 3).

Descriptive statistics were implemented through use of statistical computer software (SPSS Version 19.0, Power and Precision Release 4.1: Biostat, Engelwood, USA). The data analysis was performed on joints individually, by grouping data in two independent sets of non-rotated joints, three sets of dependent joints (on the side of the rotation, opposite side of elevation) and three sets of non-dependent joints (side of elevation) at 2°, 4° and 6° of rotation (Figure 1). The paired *t*-test and interclass correlation coefficient (ICC) were used to quantify the

repeatability of NA, PT, SI and FAD measurements between the two independent sessions performed with the standard hip extended view. An ICC of 1 indicates perfect agreement, and an ICC of 0 indicates no agreement. The repeatability for the SC was evaluated in the chi-squared test; in some statistical analyses the seven values acquired for SC (0–6), were directly converted into a numerical scale in which the same values were maintained. One-way ANOVA followed by the post-hoc LSD test was used to evaluate whether mean variable values of NA, PT, SI, SC and FAD differed significantly among the studied groups: standard, 2°, 4° and 6° of pelvic rotation, on dependent and non-dependent sides.

RESULTS

The mean asymmetry in IHD was 0.69 ± 0.74 mm. The ICC used to quantify the repeatability of NA, PT, SI and FAD between the two independent sessions with the standard hip extended view showed a positive and statistically significant result ($P < 0.05$ in all variables). The *t*-test was never significant ($P > 0.05$; Table 1). The SC values were similar in both measurement sessions when using normal positioning ($P > 0.05$, chi-squared test).

The NA and FAD did not show statistically significant mean differences at any of the degrees of rotated pelvis ($P > 0.05$), although there was a tendency for both parameters to increase on the non-dependent side (Tables 2 and 6, respectively).

The PT showed a slight increase with the degree of rotation on the dependent side and a slight de-

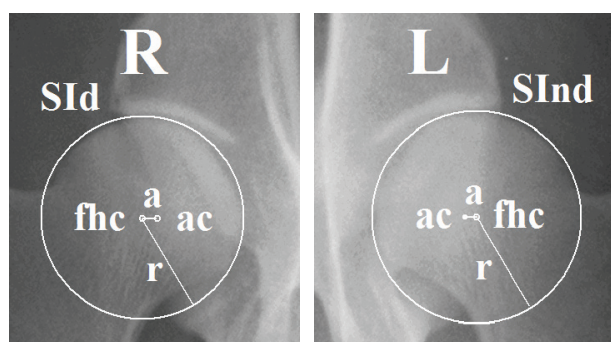


Figure 4. Magnification of right (R) and left (L) hip joints from Figure 2. The femoral head subluxation index (SI) was obtained by drawing a line (a) between the centre of the femoral head (fhc) and the acetabular centre (ac) and dividing by the radius (r) of the femoral head on the dependent (SIId) and non-dependent (SInd) sides

Table 1. Evaluation of repeatability for the four parameters using the interclass correlation coefficient and limits of agreement for 95% CI of the mean of the differences in the two measurements

Parameter	ICC	LA for 95% CI		\bar{d}	LA for 95% CI		P-value
		LB	UB		LB	UB	
NA	0.894	0.772	0.953	0.67	-1.39	0.56	0.069
PT	0.994	0.986	0.997	-0.08	-0.15	0.13	0.90
SI	0.900	0.783	0.955	0.01	0.00	0.02	0.17
FAD	0.886	0.755	0.949	0.10	-0.36	0.16	0.44

FAD = femoral head-acetabular distance, NA = Norberg angle, PT = pelvic thickness, SI = subluxation index, CI = confidence interval, \bar{d} = mean of the differences, ICC = interclass correlation coefficient, LA = limits of agreement, LB = lower boundary, UB = upper boundary

doi: 10.17221/127/2016-VETMED

Table 2. Descriptive statistical data for the normal Norberg angle in degrees, according to the degree of pelvic rotation on the dependent (Dep) and non-dependent (Non-dep) side

Rotation degree	N	Mean NA ± SE	Min.	Max.	Mean 95% CI		
					LB	UB	
Dep	0°	24	105.5 ± 0.71	100	115	104.1	107.0
	2°	24	105.4 ± 0.81	99	117	103.7	107.1
	4°	24	105.1 ± 0.83	100	117	103.4	106.8
	6°	24	105.6 ± 0.81	99	117	103.9	107.3
Non-dep	2°	24	106 ± 0.70	100	115	104.5	107.4
	4°	24	106.4 ± 0.84	100	120	104.7	108.1
	6°	24	107.3 ± 0.93	100	117	105.3	109.2

CI = confidence interval, LB = lower boundary, N = number of cases, NA = Norberg angle, SE = Standard error, UB = upper boundary

crease on the non-dependent side, in some cases with significant differences ($P < 0.05$; Table 3).

The SI and SC showed an increase with the degree of rotation on the dependent side and a decrease on the non-dependent side, sometimes with significant differences (Tables 4 and 5, respectively).

DISCUSSION

Hip dysplasia can affect more than 40% of dogs of various breeds (Comhaire et al. 2009; Ginja et

Table 3. Descriptive statistical data for normal pelvic thickness in millimetres, according to the degree of pelvic rotation on the dependent (Dep) and non-dependent (Non-dep) side

Rotation degree	N	Mean PT ± SE	Min.	Max.	Mean 95% CI		
					LB	UB	
Dep	0°	24	24.84 ± 0.62 ^a	19.09	29.63	23.56	26.12
	2°	24	25.74 ± 0.64 ^{a,b,c}	19.49	31.02	24.42	27.07
	4°	24	26.49 ± 0.63 ^{a,b}	20.09	31.22	25.18	27.80
	6°	24	27.33 ± 0.66 ^b	21.08	33.01	25.95	28.70
Non-dep	2°	24	24.57 ± 0.63 ^{a,c}	18.49	29.63	23.26	25.88
	4°	24	24.37 ± 0.67 ^{a,c}	17.90	29.63	22.98	25.75
	6°	24	24.25 ± 0.66 ^{a,c}	17.70	30.01	22.88	25.63

CI = confidence interval, LB = lower boundary, N = number of cases, PT = pelvic thickness, SE = Standard error, UB = upper boundary

^{a-c}Mean values with different superscripts are statistically different in the ANOVA post-hoc LSD test ($P < 0.05$)

Table 4. Descriptive statistical data for the normal femoral head subluxation index according to the degree of pelvic rotation on the dependent (Dep) and non-dependent (Non-dep) side

Rotation degree	N	Mean SI ± SE	Min.	Max.	Mean 95% CI		
					LB	UB	
Dep	0°	24	0.14 ± 0.01 ^a	0.08	0.28	0.12	0.16
	2°	24	0.16 ± 0.01 ^a	0.06	0.27	0.13	0.18
	4°	24	0.19 ± 0.01 ^b	0.09	0.29	0.17	0.21
	6°	24	0.24 ± 0.01 ^c	0.10	0.36	0.21	0.26
Non-dep	2°	24	0.10 ± 0.01 ^d	0.02	0.21	0.08	0.13
	4°	24	0.09 ± 0.01 ^d	0.03	0.19	0.07	0.11
	6°	24	0.08 ± 0.01 ^d	0.02	0.19	0.06	0.10

CI = confidence interval, LB = lower boundary, N = number of cases, SE = standard error, SI = femoral head subluxation index, UB = upper boundary

^{a-d}Mean values with different superscripts are statistically different in the ANOVA post-hoc LSD test ($P < 0.05$)

al. 2009) and the progress made in decreasing the incidence of canine HD remains low (Verhoeven et al. 2010; Smith et al. 2012). Accurate screening for canine HD is essential to make adequate recommendations regarding breeding programmes (Chalmers et al. 2013) and treatment of canine HD (Verhoeven et al. 2010). Radiographic assessment and measurements on the standard VDHE view are the basis of the main international HD scor-

Table 5. Descriptive statistical data for the normal femoral head subluxation category after direct conversion into a numerical scale with the same value, according to the degree of pelvic rotation on the dependent (Dep) and non-dependent (Non-dep) side

Rotation degree	N	Mean SC ± SE	Min.	Max.	Mean 95% CI		
					LB	UB	
Dep	0°	24	1.50 ± 0.13 ^a	0.00	3.00	1.22	1.78
	2°	24	2.29 ± 0.14 ^b	1.00	3.00	2.00	2.58
	4°	24	2.54 ± 0.12 ^b	1.00	3.00	2.29	2.79
	6°	24	2.96 ± 0.07 ^c	2.00	4.00	2.81	3.11
Non-dep	2°	24	1.42 ± 0.12 ^a	1.00	3.00	1.17	1.66
	4°	24	1.17 ± 0.17 ^{a,d}	0.00	3.00	0.82	1.51
	6°	24	0.88 ± 0.17 ^d	0.00	3.00	0.52	1.23

CI = confidence interval, LB = lower boundary, N = number of cases, SE = standard error, SC = femoral head subluxation category, UB = upper boundary

^{a-d}Mean values with different superscripts are statistically different in the ANOVA post-hoc LSD test ($P < 0.05$)

Table 6. Descriptive statistical data for the normal femoral head-acetabular distance in millimetres according to the degree of pelvic rotation on the dependent (Dep) and non-dependent (Non-dep) side

Rotation degree	N	Mean FAD ± SE	Min.	Max.	Mean 95% CI	
					LB	UB
0°	24	4.07 ± 0.27	1.59	8.15	3.52	4.62
Dep	2°	3.99 ± 0.26	1.79	7.16	3.44	4.53
	4°	4.06 ± 0.28	1.59	7.56	3.49	4.63
	6°	4.12 ± 0.30	1.39	7.56	3.50	4.74
Non-dep	2°	4.22 ± 0.27	1.79	7.16	3.65	4.78
	4°	4.22 ± 0.28	1.79	7.56	3.65	4.79
	6°	4.38 ± 0.29	1.59	7.36	3.79	4.98

CI = confidence interval, FAD = femoral head-acetabular distance, LB = lower boundary, N = number of cases, SE = standard error, UB = upper boundary

ing systems: FCI, OFA and BVA/KC (Genevois et al. 2007; Skurkova et al. 2010; Chalmers et al. 2013). Therefore, proper positioning and optimal exposure technique are essential prerequisites for radiographs of sufficient diagnostic quality to allow accurate HD assessment (Genevois et al. 2007; Thompson et al. 2007; Bausman and Wendelburg 2010). Pelvic rotation over the longitudinal axis changes hip radiographic morphology (Genevois et al. 2007; Volta et al. 2013; Martins et al. 2016).

Previously published works have reported the relationship between pelvis rotation and the projected DAE and NA on the dependent side and non-dependent side (Genevois et al. 2007; Skurkova et al. 2010), although not always with a sound scientific basis. In this study, we studied only normal hips or those with slight signs of HD, because in these kinds of hips an alteration of the studied radiographic parameters may acquire more importance for canine HD scoring purposes. In contrast, signs associated with degenerative joint disease are more important for scoring moderate and severe HD. The NA is currently one important classification criterion and has been adopted by the FCI, BVA/KC and many European kennel clubs (Genevois et al. 2007; Skurkova et al. 2010). Factors such as age, sedation or anaesthesia, osteoarthritis (Vandekerckhove et al. 2003; Gold et al. 2009) and pelvic rotation may influence NA scores (Genevois et al. 2007; Skurkova et al. 2010). In a previous study, using a canine-bone model with changes of between 0° and 30° of pelvic rotation along the short

body axis, the NA in VDHE views did not change (Bausman and Wendelburg 2010).

In this study using a cadaveric model, the normal VDHE view showed a very low mean IHD asymmetry (less than 1°), similar to a previous study (Martins et al. 2016) and the mean NA did not show statistically significant changes with pelvis rotation (2° to 6°), either on the dependent or non-dependent side, which is not in agreement with some other studies (Genevois et al. 2007; Skurkova et al. 2010). In fact, the NA showed a consistent tendency to increase on the non-dependent side and greater degrees of rotation may result in statistically significant NA differences. However, we think that this factor is not of great practical importance, as radiographs with large pelvic rotation are excluded from HD evaluation. The FAD showed a similar variation to the NA; this is understandable since the two variables result from the relationship between the same anatomical structures, i.e. the centre of the femoral head and CAR. These results can be explained by the similar level in the dorsal plane of the centre of the femoral head and the CAR, resulting in a similar radiographic distortion with rotation. The slight increase of the NA on the non-dependent side could be associated with some distortion of the CAR due to the overlapping of the craniodorsal aspect of the dorsal acetabular edge (more dorsal thickness, more lateral distortion).

The changes in the PT are essentially due to the relationship between the sagittal thickness of the pelvis at this anatomical level and the periphery of the X-ray beam being more perpendicular on the dependent rotation side, with more distortion and the inverse distortion phenomenon on the non-dependent side.

The increase of SC and SI on the dependent side and their reduction on the opposite side are consistent with expectations and with the published literature (Fluckiger et al. 1999; Genevois et al. 2007; Thompson et al. 2007). The DAE and other important acetabular structures, such as the cranial acetabular edge, are projected more medially on the dependent side and more laterally on the non-dependent side, possibly because they are located in a more dorsal anatomical plane than the centre of the femoral head, resulting in the increase and reduction of the projected radiographic subluxation, respectively. The SI was investigated in a special VDHE view using a stress technique in an attempt to quantify the maximal dislocation of the femoral

doi: 10.17221/127/2016-VETMED

head from the acetabulum; it was concluded that pelvis rotation along the long axis does not significantly change the SI (Fluckiger et al. 1999). Our study using the standard VDHE view found some statistically significant changes in the dependent (higher SI values) in bigger rotations (4° and 6°). However, on the non-dependent side (lower SI values) the reduction between 2° and 6° was very small ($P > 0.05$). The similarity of mean SI values on the non-dependent side (2°, 4° and 6°) can be associated with the sample (overall lower mean subluxation), which becomes non-existent subluxation in some joints with small contralateral pelvis rotation or with some inaccuracy in acetabular delimitation that assumes more importance at lower SI values. The SC is a subjective parameter used in the BVA/KC scoring system (Gibbs 1997; Dennis 2012). Our results are in agreement with reports in the literature that DAE projection and consequently SC are greatly affected by pelvis rotation, with a negative and positive effect on the dependent and non-dependent side, respectively (Thompson et al. 2007; Dennis 2012). However, in scoring systems that use both hip scores, the negative effect on the hip (dependent) is cancelled out by the positive effect on the contralateral hip (non-dependent) and the total HD score is acceptably accurate (Dennis 2012).

The cadaveric animal model used in this study was adequate as the normal pelvic anatomical structure was preserved. However, the application of femoral pins for femoral extension and internal rotation, as well as the altered stiffness and contracture of the soft tissue of the hip joints of dead animals can result in a different rotation of the femoral head within the acetabulum, and consequently, changes in the relationship between these anatomical structures. In the present study, digital radiography and computer software analyses were used to promote better accuracy in the performed measurements (Comhaire et al. 2009). In the future, canine HD will continue to be a challenging disease given that the genetic architecture of the disease is complex and there is no ideal medical or surgical treatment (Ginja et al. 2015). The same can be said about canine HD diagnosis, because no ideal radiographic technique has been found and the development of an ideal genetic screening test is difficult. Analysing the most recent investigations regarding canine HD and the NA, we can say that despite criticism of the NA, this parameter continues to be valuable due to its high and quantifiable correlation with final scoring (Culp et al.

2006; Janssens et al. 2013). Our work may contribute to resolving the controversy regarding the NA, SC and SI and comprehension. Future clinical studies are needed to validate these results in live animals.

In conclusion, the NA and FAD parameters did not change with pelvic rotation. The SI, SC and PT were affected by pelvic rotation; they were overvalued on the side of rotation and undervalued on the contralateral side of rotation. Pelvic rotation, along its long axis, impairs classification in hip dysplasia scoring systems that are based on the animal's worst joint, as the greater spacing between the femoral head/cranial acetabular edge is associated with joint incongruence. However, it may benefit classification in schemes based on both hip scores, as the non-dependent side shows a slight increase in NA.

REFERENCES

- Adams WM, Dueland RT, Daniels R, Fialkowski J, Nordheim EV (2000): Comparison of two palpation, four radiographic and three ultrasound methods for early detection of mild to moderate canine hip dysplasia. *Veterinary Radiology and Ultrasound* 41, 484–490.
- Andronescu A, Kelly L, Kearney MT, Lopez MJ (2015): Associations between early radiographic and computed tomographic measures and canine hip joint osteoarthritis and maturity. *American Journal of Veterinary Research* 76, 19–27.
- Bausman JA, Wendelburg KL (2010): Evaluation of the effect of pelvic tilt in the coronal plane on the Norberg angle measured in ventrodorsal radiographic views of a canine hip joint bone model. *American Journal of Veterinary Research* 71, 1348–1353.
- Chalmers HJ, Nykamp SN, Lerer A (2013): The Ontario Veterinary College Hip Certification Program – Assessing inter- and intra-observer repeatability and comparison of findings to those of the Orthopedic Foundation for Animals. *Canadian Veterinary Journal* 54, 42–46.
- Comhaire FH, Criel AC, Dassy CA, Guevar PG, Snaps FR (2009): Precision, reproducibility, and clinical usefulness of measuring the Norberg angle by means of computerized image analysis. *American Journal of Veterinary Research* 70, 228–235.
- Culp WTN, Kapatkin AS, Gregor TP, Powers MY, McKelvie PJ, Smith GK (2006): Evaluation of the Norberg angle threshold: A comparison of Norberg angle and distraction index as measures of coxofemoral degenerative joint disease susceptibility in seven breeds of dogs. *Veterinary Surgery* 35, 453–459.

- Dennis R (2012): Interpretation and use of BVA/KC hip scores in dogs. In *Practice* 34, 178–194.
- Fluckiger M (1995): The standardised analysis of radiographs for hip dysplasia in dogs. Objectifying a subjective process. *The European Journal of Companion Animal Practice* 5, 39–44.
- Fluckiger MA, Friedrich GA, Binder H (1999): A radiographic stress technique for evaluation of coxofemoral joint laxity in dogs. *Veterinary Surgery* 28, 1–9.
- Genevois JP, Cachon T, Fau D, Carozzo C, Viguier E, Collard F, Remy D (2007): Canine hip dysplasia radiographic screening. Prevalence of rotation of the pelvis along its length axis in 7,012 conventional hip extended radiographs. *Veterinary and Comparative Orthopaedics and Traumatology* 20, 296–298.
- Gibbs C (1997): The BVA/KC scoring scheme for control of hip dysplasia: interpretation of criteria. *Veterinary Record* 13, 275–284.
- Ginja MM, Ferreira AJ, Silvestre M, Gonzalo-Orden JM, Llorens-Pena MP (2006): Repeatability and reproducibility of distraction indices in PennHIP examinations of the hip joint in dogs. *Acta Veterinaria Hungarica* 54, 387–392.
- Ginja MMD, Gonzalo-Orden JM, Melo-Pinto P, Bulas-Cruz J, Orden MA, San-Roman F, Llorens-Pena MP, Ferreira AJA (2008): Early hip laxity examination in predicting moderate and severe hip dysplasia in Estrela mountain dogs. *Journal of Small Animal Practice* 49, 641–646.
- Ginja MMD, Ferreira AJ, Jesus SS, Melo-Pinto P, Bulas-Cruz J, Orden MA, San-Roman F, Llorens-Pena P, Gonzalo-Orden JM (2009): comparison of clinical, radiographic, and magnetic resonance imaging methods for early prediction of canine hip laxity and dysplasia. *Veterinary Radiology and Ultrasound* 50, 135–143.
- Ginja MMD, Silvestre AM, Gonzalo-Orden JM, Ferreira AJ (2010): Diagnosis, genetic control and preventive management of canine hip dysplasia: a review. *Veterinary Journal* 184, 269–276.
- Ginja M, Gaspar AR, Ginja C (2015): Emerging insight into the genetic basis of canine hip dysplasia. *Veterinary Medicine: Research and Reports* 6, 193–202.
- Gold RM, Gregor TP, Huck JL, McKelvie PJ, Smith GK (2009): Effects of osteoarthritis on radiographic measures of laxity and congruence in hip joints of Labrador Retrievers. *Journal of the American Veterinary Medical Association* 235, 1549–1554.
- Janssens L, De Ridder M, Verhoeven G, Gielen I, van Bree H (2013): Comparing Norberg angle, linear femoral overlap and surface femoral overlap in radiographic assessment of the canine hip joint. *Journal of Small Animal Practice* 55, 135–138.
- Lust G, Todhunter RJ, Hollis NE, Dykes NL, Williams AJ, Burton-Wuster NI, Farese JP (2001): Comparison of three radiographic methods for diagnosis of hip dysplasia in eight-month-old dogs. *Journal of the American Veterinary Medical Association* 219, 1242–1246.
- Martins J, Ferreira AJ, Ginja MM (2012): Morphometric assessment of the hip joint in the Estrela mountain dog breed. *Veterinary and Comparative Orthopaedics and Traumatology* 25, 202–210.
- Martins J, Colaço BJ, Ferreira AJ, Ginja MM (2016): Analysis of pelvic rotation on the standard hip ventrodorsal extended radiographic view. *Veterinary and Comparative Orthopaedics and Traumatology* 29, 68–74.
- Ohlerth S, Lang J, Busato A, Gaillard C (2001): Estimation of genetic population variables for six radiographic criteria of hip dysplasia in a colony of Labrador retrievers. *American Journal of Veterinary Research* 62, 846–852.
- Skurkova L, Hluchy M, Lackova M, Mihalova M, Ledecy V (2010): Relation of the Norberg angle and the position of the femoral head centre to the dorsal acetabular edge in the evaluation of canine hip dysplasia. *Veterinary and Comparative Orthopaedics and Traumatology* 23, 433–438.
- Smith GK, Lawler DF, Biery DN, Powers MY, Shofer F, Gregor TP, Karbe GT, McDonald-Lynch MB, Evans RH, Kealy RD (2012): Chronology of hip dysplasia development in a cohort of 48 Labrador Retrievers followed for life. *Veterinary Surgery* 41, 20–33.
- Thompson R, Roe SC, Robertson ID (2007): Effects of pelvic positioning and simulated dorsal acetabular rim remodeling on the radiographic shape of the dorsal acetabular edge. *Veterinary Radiology and Ultrasound* 48, 8–13.
- Tomlinson JL, Johnson JC (2000): Quantification of measurement of femoral head coverage and Norberg angle within and among four breeds of dogs. *American Journal of Veterinary Research* 61, 1492–1500.
- Vandekerckhove PMFP, Janssens LAA, Ballieu BCW (2003): The influence of epidural anesthesia on femoral overlap and Norberg angle in the hip joint of young dysplastic dogs. *Veterinary and Comparative Orthopaedics and Traumatology* 16, 127–131.
- Verhoeven G, Coopman F, Duchateau L, Saunders JH, van Rijssen B, van Bree H (2007): Interobserver agreement in the diagnosis of canine hip dysplasia using the standard ventrodorsal hip extended radiographic method. *Journal of Small Animal Practice* 48, 387–393.
- Verhoeven G, Fortrie RR, Duchateau L, Saunders JH, Van Ryssen B, Van Bree H, Coopman F (2010): The effect of a technical quality assessment of Hip-extended radiographs on interobserver agreement in the diagnosis of canine hip Dysplasia. *Veterinary Radiology and Ultrasound* 51, 498–503.

doi: 10.17221/127/2016-VETMED

Volta A, Piccionello AP, Salvaggio A, Dini F, Bonnazzi M, Manfredi S, Tambella AM, Gnudi G (2013): Effect of pelvic inclination and torsional deformity on canine acetabular morphology with computed tomography. *Veterinary*

and *Comparative Orthopedics and Traumatology* 26, 440–444.

Received: August 24, 2016

Accepted after corrections: February 22, 2017