

Thoracoscopic-assisted lung lobectomy using hem-o-lok clips in a dog with lung lobe torsion: a case report

S.Y. LEE¹, S.J. PARK¹, S.H. SEOK¹, Y.K. KIM², H.C. LEE¹, S.C. YEON¹

¹College of Veterinary Medicine, Gyeongsang National University, Jinju, Republic of Korea

²Haeundae Animal Medical Center, Busan, Republic of Korea

ABSTRACT: An eleven-year-old, 3-kg, intact female Maltese was presented for depression, anorexia and dyspnoea. Thoracic radiographs showed right-side pleural effusion, a vesicular emphysema pattern and consolidation of the right middle lung lobe. A presumptive diagnosis of lung lobe torsion (LLT) in the right middle lobe was made using a computed tomography scan. Thoracoscopic exploration was performed without one-lung ventilation in the right hemithorax. Pleural fluid and engorgement of the torted lung lobe were observed. A total lung lobectomy of the right middle lung lobe was performed with a thoracoscopic-assisted procedure using hem-o-lok clips applied to the hilus. The dog was discharged three days after surgery, and no recurrence of the clinical signs of disease related to the respiratory system was observed during the follow-up time period of six months. Based on these findings, we conclude that thoracoscopic-assisted lung lobectomy using hem-o-lok clips is a minimally invasive surgical alternative to thoracotomy and successful operative intervention for lung lesions in small breed dogs.

Keywords: thoracoscopy; lung lobe torsion; lung lobectomy; hem-o-lok clip; dog

Lung lobe torsion (LLT) was reported as an unusual condition in dogs and results from physical displacement and twisting of a lung lobe around its bronchovascular pedicle (Gallagher 1993). LLT has been described as secondary to predisposing conditions or as a spontaneous occurrence without underlying disease (Lord et al. 1973). LLT results in lung lobe atelectasis (Gallagher 1993), and total lobectomy of the involved lung lobe is the treatment of choice.

Thoracoscopy has been performed as a diagnostic and therapeutic procedure in animals (De Rycke et al. 2001; Kovak et al. 2002; Lansdowne et al. 2005; Plesman et al. 2011). However, with thoracoscopy, it is difficult to manipulate intrathoracic structures with endoscopic surgical instruments in the thoracic cavity, especially in a small thorax. In humans, thoracoscopic-assisted procedures have been developed, and these techniques were reported to reduce postoperative pain and morbidity with minimal surgical exposure (De Letter and Proot 1995). Laksito et al. (2010) also described the advantages of minimally invasive thoracoscopic-assisted lung lobectomy in dogs. The purpose of

this report is to describe a thoracoscopic-assisted method using hem-o-lok clips as an alternative suturing technique for lung lobectomy in a small dog.

Case description

An eleven-year-old, intact female Maltese, of 3-kg bodyweight, was presented with a three day history of depression, anorexia and dyspnoea. On thoracic auscultation, decreased cardiopulmonary sounds were detected. A complete blood count, electrolytes and serum biochemical analyses were performed. Neutrophilia with a count of 34.1×10^3 neutrophils/ μl (normal range $2.9\text{--}10.6 \times 10^3$ neutrophils/ μl) was the only abnormality found. Thoracic radiographs showed a right side pleural effusion, vesicular emphysema pattern and consolidation of the right middle lung lobe. Apart from these findings, bronchial collapse with a tapering angle around this collapsed region of the bronchus was also revealed by computed tomography (Figure 1). A presumptive diagnosis of LLT in the right middle lobe was established.

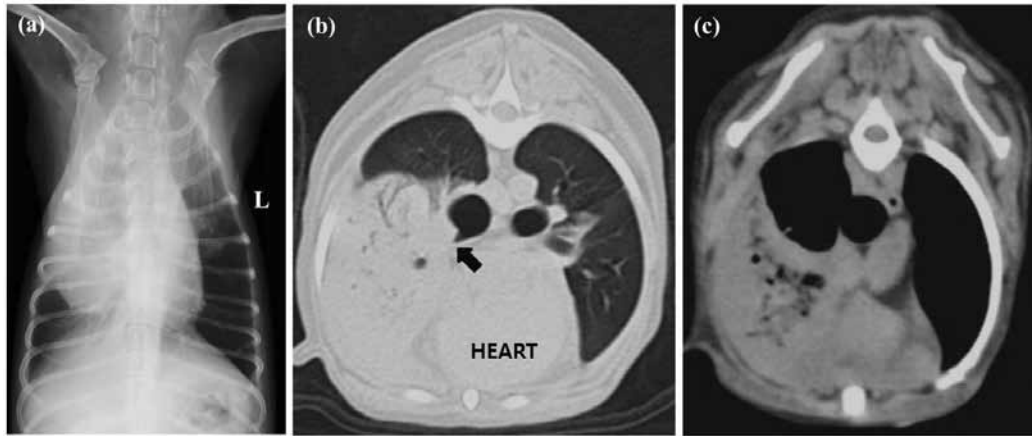


Figure 1. (a) Ventrodorsal thoracic radiograph showing a right side pleural effusion and consolidation of the right middle lung lobe. (b) Thoracic computed tomography. Lung window (window = 1200, level = -600). A tapering angle immediately proximal to bronchial collapse of the right middle lung lobe is shown (arrow). (c) Lung window (window = 400, level = 40). The vesicular emphysema pattern is shown in the right middle lung lobe parenchyma

The dog was pre-medicated with 0.02 mg/kg acepromazine (Sedaject, Samu Median, Korea) and 0.2 mg/kg butorphanol (Butophan, Myungmoon pharm Co., Ltd., Korea) intravenously. General anaesthesia was induced with 3 mg/kg of propofol (Provive 1%, Myungmoon pharm Co., Ltd., Korea) and maintained with isoflurane in 100% oxygen via an endotracheal tube without pulmonary exclusion. A total dose of 2 mg/kg of 0.5% bupivacaine (Bupivacaine HCl 0.5%, Myungmoon Pharm Co., Ltd., Korea) was used to achieve intercostal nerve blocks on spaces adjacent to the portal and incisional sites.

The dog was positioned in left lateral recumbency, and the right hemithorax was clipped and surgically prepared. A 2-portal technique was used with two 5-mm cannulae. The first cannula was placed on the middle of the right 10th intercostal space (thoracoscope) and the second on the dorsal one-third of the right 6th intercostal space (instrument). A 5-mm skin incision was made in the middle of the 10th intercostal space, and Halsted hemostat forceps were used to bluntly penetrate the thoracic

wall. Then, a 5-mm cannula was inserted into the thoracic wall; the second cannula was inserted in the same manner. A 30° forward-oblique, 5-mm thoracoscope (Panoview Plus, Richard Wolf GmbH, Germany) and atraumatic forceps were inserted through the cannula, respectively. Abnormalities encountered were serosanguineous pleural fluid and engorgement of the torsed right middle lung lobe. After localisation of the LLT, a 4-cm intercostal mini-thoracotomy was made over the second portal site in the right 6th intercostal space, directly over the lesion. With retraction of the torsed lobe through the thoracotomy, three of 5-mm hem-o-lok clips (Weck Hem-o-lok, Teleflex Medical, USA) were placed across the hilus of the lobe using an endoscopic clip applicator (Endo5, Teleflex medical, USA) under thoracoscopic observation, and the hilus was resected using endoscopic scissors (Figure 2). Then, the resected lobe was exteriorised through the mini-thoracotomy. Following lobectomy, the pleural cavity was lavaged and air seal from the lobectomy site was verified during the lavage. The thorax was closed routinely with an

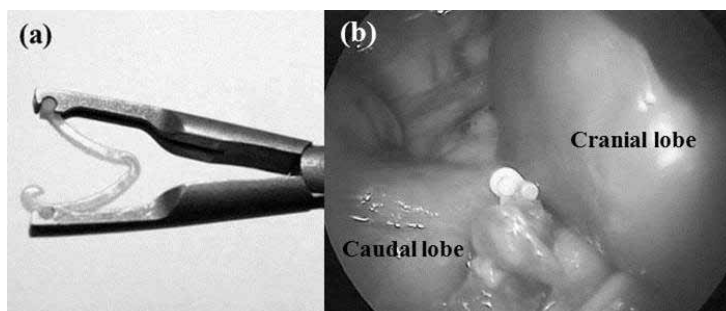


Figure 2. (a) Hem-o-lok clips and endoscopic clip applicator. (b) After removal of the middle

indwelling 16-French thoracostomy tube, which was removed the day after surgery.

The dog recovered uneventfully, and no complication associated with the surgery was observed. Postoperative analgesic treatment was performed with 4.4 mg/kg carprofen (Rimadyl, Pfizer, USA) for three days.

No underlying diseases were identified in the affected lung lobe on histology. The dog was discharged to the owner three days after surgery. Up to six months postoperatively, no evidence of clinical signs of disease in the respiratory system have been observed.

DISCUSSION AND CONCLUSIONS

The clinical signs seen in this dog were, in general, similar to those described in previous reports of LLT (Neath et al. 2000; Schultz et al. 2009). Consolidation of the right cranial and middle lung lobe, and a vesicular emphysematous pulmonary parenchymal pattern were revealed by radiography and computed tomography. Additionally, thoracic computed tomography revealed bronchial collapse with a tapering angle proximal and distal to this collapsed region of the bronchus. Thoracoscopy permitted localisation and definitive diagnosis of LLT. The torsed right middle lung lobe showing a liver-like appearance induced collapse and atelectasis of the cranial lung lobe by cranial compression. Just after removal of the middle lung lobe, however, the cranial lung lobe gradually returned to its normal appearance, so that lobectomy was not performed.

The use of thoracoscopy for diagnostic and therapeutic procedures has increased in veterinary medicine owing to its advantages of reduced postoperative morbidity and rapid recovery (Walsh et al. 1999; De Rycke et al. 2001; Brissot et al. 2003). Among indications, thoracoscopy has successfully been used on lung lobectomies in dogs with tumours (Lansdowne et al. 2005; Laksito et al. 2010), foreign bodies (Pelaez and Jolliffe 2012) and bullous emphysema (Brissot et al. 2003). The introduction of safe linear stapling devices has made thoracoscopic-assisted segmental long resections possible in human medicine (De Letter and Proot 1995). Previous veterinary reports related to thoracoscopic lobectomy have also used automatic stapling equipment as an alternative suturing technique, and the patients undergoing thoracoscopic lobectomy were medium or large breed dogs weighing

more than 15 kg (Brissot et al. 2003; Lansdowne et al. 2005; Laksito et al. 2010; Pelaez and Jolliffe 2012). However, the stapling device is difficult to position in a small thorax owing to the size of the cartridges (He et al. 1996), as was the case in this Maltese dog. In the present case, 5-mm hem-o-lok clips were applied to the ligature in the hilus of the lung lobe instead of a linear stapler because of the small size of the thoracic cavity and lung lobe hilum. Exclusion of adjacent tissue was not troublesome in this surgical technique, and precise ligation of the hilus was achieved without haemorrhage and air leakage.

One-lung ventilation is recommended to increase the amount of space available in the thoracic cavity and to improve visibility and surgical exposure and size of the operating field (Kudnig et al. 2003; Pelaez and Jolliffe 2012). One-lung ventilation requires selective intubation with specially designed endotracheal tubes (Pelaez and Jolliffe 2012) or mainstem bronchial blockade to ventilate selectively one main stem bronchus (Schmiedt 2009). However, these products are designed for humans, and therefore, it can be challenging to place them in smaller dogs. In the present case, a thoracoscopic-assisted procedure was performed without one-lung ventilation, and the whole surgical process was finished without difficulty.

Thoracoscopic-assisted procedures could represent an alternative when there is poor visualisation during thoracoscopy (He et al. 1996). This technique is reported to minimise postoperative pain and morbidity without compromising surgical exposure (De Letter and Proot 1995). The first reports of thoracoscopic-assisted lung lobectomy in veterinary literature described thoracoscopic-assisted mini-thoracotomy as an effective, minimally invasive approach for ipsilateral hemithorax exploration and lung lobectomy (Laksito et al. 2010). In this study, a thoracoscopic-assisted technique was used, but was modified in consideration of the small size of the dog. Except for the camera port, the only instrument port was located in a position that can be easily converted into a mini-thoracotomy to facilitate exteriorisation of the lung lobe, and consequently two-portal access was achieved. With the use of thoracoscopic-assisted procedures, surgeons may perform more technically challenging procedures and decrease the need for conversion (Radlinsky 2009).

In summary, this study has demonstrated the feasibility of thoracoscopic-assisted lung lobectomy

using hem-o-lok clips as an alternative suturing technique. This technique is accessible and financially cheap, and the incision length is shorter than that of conventional open thoracotomy. Further studies are warranted to investigate optimum portal placement and surgical techniques for accessing individual lung lobes with thoracoscopy using hem-o-lok clips.

REFERENCES

- Brissot HN, Dupre GP, Bouvy BM, Paquet L (2003): Thoracoscopic treatment of bullous emphysema in 3 dogs. *Veterinary Surgery* 32, 524–529.
- De Letter J, Proot L (1995): Thoracoscopic assisted lobectomy. *Surgical Laparoscopy and Endoscopy* 5, 12–16.
- De Rycke LM, Gielen IM, Polis I, Van Ryssen B, van Bree HJ, Simoens PJ (2001): Thoracoscopic anatomy of dogs positioned in lateral recumbency. *Journal of the American Animal Hospital Association* 37, 543–548.
- Gallagher LA (1993): Lung lobe torsion. In: Bojrab MJ (eds.): *Disease Mechanisms in Small Animal Surgery*. 2nd ed. Lea & Febiger, Philadelphia. 386–387.
- He J, Yang Y, Chen M (1996): Lobectomy by video-assisted thoracoscopic surgery. *Zhonghua wai ke za zhi [Chinese Journal of Surgery]* 34, 76–78.
- Kovak JR, Ludwig LL, Bergman PJ, Baer KE, Noone KE (2002): Use of thoracoscopy to determine the etiology of pleural effusion in dogs and cats: 18 cases (1998–2001). *Journal of the American Veterinary Medical Association* 221, 990–994.
- Kudnig ST, Monnet E, Riquelme M, Gaynor JS, Corliss D, Salman MD (2003): Effect of one-lung ventilation on oxygen delivery in anesthetized dogs with an open thoracic cavity. *American Journal of Veterinary Research* 64, 443–448.
- Laksito MA, Chambers BA, Yates GD (2010): Thoracoscopic-assisted lung lobectomy in the dog: report of two cases. *Australian Veterinary Journal* 88, 263–267.
- Lansdowne JL, Monnet E, Twedt DC, Dernell WS (2005): Thoracoscopic lung lobectomy for treatment of lung tumors in dogs. *Veterinary Surgery* 34, 530–535.
- Lord PE, Greiner TP, Greene RW, DeHoff WD (1973): Lung lobe torsion in the dog. *Journal of the American Animal Hospital Association* 9, 473–482.
- Neath PJ, Brockman DJ, King LG (2000): Lung lobe torsion in dogs: 22 cases (1981–1999). *Journal of the American Veterinary Medical Association* 217, 1041–1044.
- Pelaez MJ, Jolliffe C (2012): Thoracoscopic foreign body removal and right middle lung lobectomy to treat pyothorax in a dog. *The Journal of Small Animal Practice* 53, 240–244.
- Plesman R, Johnson M, Rurak S, Ambrose B, Shmon C (2011): Thoracoscopic correction of a congenital persistent right aortic arch in a young cat. *Canadian Veterinary Journal* 52, 1123–1128.
- Radlinsky MG (2009): Complications and need for conversion from thoracoscopy to thoracotomy in small animals. *Veterinary Clinics of North America Small Animal Practice* 39, 977–984.
- Schmiedt C (2009): Small animal exploratory thoracoscopy. *Veterinary Clinics of North America Small Animal Practice* 39, 953–964.
- Schultz RM, Peters J, Zwingenberger A (2009): Radiography, computed tomography and virtual bronchoscopy in four dogs and two cats with lung lobe torsion. *The Journal of Small Animal Practice* 50, 360–363.
- Walsh PJ, Remedios AM, Ferguson JF, Walker DD, Cantwell S, Duke T (1999): Thoracoscopic versus open partial pericardectomy in dogs: comparison of post-operative pain and morbidity. *Veterinary Surgery* 28, 472–479.

Received: 2013–10–31

Accepted after corrections: 2014–07–10

Corresponding Author:

Seong Chan Yeon, Gyeongsang National University, College of Veterinary Medicine, Jinju 660-701, Republic of Korea
Tel. +82 55 772 2348, E-mail: scyeon@gnu.ac.kr
