

Clinical application of bone forming peptide-1 for nonunion fracture healing in a dog with Cushing's disease: a case report

S. KIM¹, K. SHIM¹, T. YOON¹, S. KANG¹

¹College of Veterinary Medicine, Chonnam National University, Gwangju, Republic of Korea

²Joint Center of Chonnam National University Hwasun Hospital, Jeonnam, Republic of Korea

ABSTRACT: A nine-year-old, female Shih Tzu dog was referred to Chonnam National University Veterinary Teaching Hospital with a non-weight bearing lameness, pain in the right forelimb, increased appetite, and dermatological changes. A complete transverse fracture of the right ulnar trochlear notch was detected on survey radiographs. Cushing's disease was diagnosed using the adrenocorticotrophic hormone test. The fracture site was repaired using an intramedullary (IM) pin, a 2.0 miniplate and screws, and 1 mg of bone forming peptide-1 (BFP-1) was applied to the fracture site. Post-operative radiographs were performed immediately, and at two and 17 weeks after the first surgery. After the first surgery, the patient fell from the bed, and the IM pin was broken. Thus, a second surgery was performed, and the broken IM pin was removed. To stimulate bone healing, we applied Matrigel containing 3 mg of BFP-1 to the fracture site 20 weeks after the first surgery. A narrowed fracture gap was seen radiographically three weeks after the second surgery, and a hard callus was observed on the cranial fracture line at eight weeks. Bone mineral density at the fracture site increased at 16 weeks. Gradual fracture healing was observed on radiographs over the 35 week period following the second surgery.

Keywords: nonunion fracture healing; bone forming peptide-1; Matrigel; Cushing's disease; dog

A nonunion is defined as a fracture in which the bone ends fail to heal, eventually leading to loss of normal bone function. A nonunion will not heal without surgical treatments that remove non-viable soft tissue, callus, and sclerosing bone, and trim the ends of the non-healed bones (Piermattei et al. 2006). Common causes of nonunions include inadequate coaptation or fixation, poor reduction or apposition of bone fragments, impaired blood supply, and loss of bone or bone fragments (Millis and Jackson 2003). Systemic diseases such as diabetes, anaemia, and Cushing's disease can also result in nonunions (Mendicino et al. 1996).

Bone grafts are widely used to treat defects in bone nonunions in human and veterinary medicine. Many studies have tried to identify stimulators of

bone formation such as vascular endothelial growth factor (VEGF), platelet-derived growth factor (PDGF) and bone morphogenetic proteins (BMPs) (Nandi et al. 2010). BMPs are low molecular weight glycoproteins and potent osteoinductive growth factors with the ability to induce new bone growth (Milovancev et al. 2007; David et al. 2009). In our previous cases of delayed union fractures in dogs, clinical application of recombinant human BMP-2 was effective in stimulating the healing of a delayed union (Kim et al. 2012b).

Most described BMP genes such as BMP-2, BMP-3, and BMP-7 are similar to the Vgr-1 gene in their mature forms. Most BMP peptides with biological activity include the mature region of BMP-7. To date, the regulation of bone generation has been

Supported from the Next-Generation BioGreen 21 Program (Grant No. PJ01135201), Rural Development Administration, Republic of Korea and the Basic Science Research Program through the National Research Foundation of Korea (NRF) funded by the Ministry of Education, Science and Technology (Grant No. 2012R1A1A2008485).

the focus of investigations into the mature form of BMP-7. New peptides from the immature form, which have osteogenic activity, have been reported in previous studies. Bone forming peptide-1 (BFP-1) is a peptide derived synthetically from BMP-7. We have previously shown the bone generating efficacy of BFP-1 (Kim et al. 2012a).

Here, we report the clinical application of BFP-1 with Matrigel to treat a nonunion fracture in a dog with Cushing's disease.

Case description

A nine-year-old female Shih Tzu dog was presented to Chonnam National University Veterinary Teaching Hospital. The owner stated that the dog had fallen down the stairs two months previously. The clinical signs included a non-weight bearing lameness and pain in the right forelimb. An increased appetite and dermatological changes were also observed. Moreover, the dog was blind as a result of severe bilateral corneal melanosis. Survey radiographs revealed a complete transverse fracture of the right ulnar trochlear notch. The patient was diagnosed with Cushing's disease based on a blood profile, abdominal ultrasound, and adreno-

corticotrophic hormone (ACTH) stimulation test. The results of serum biochemistry analyses revealed increased albumin, alkaline phosphatase, alanine aminotransferase, and cholesterol. An increased cortisol concentration was detected on a post-ACTH test.

Surgery was performed to repair the ulnar trochlear notch fracture. The patient was premedicated with 5 mg/kg cimetidine (H-2[®] AMP; JW Pharmaceutical, Republic of Korea) and 20 mg/kg cefazolin (Cefazoline CKD INJ[®] 1 g; Chong Kun Dang Pharm, Republic of Korea) preoperatively by intravenous injection. Anaesthesia was induced with 48 µg/kg medetomidine (Domitor[®]; Pfizer Animal Health Korea, Seoul, Republic of Korea), 3 mg/kg tiletamine/zolazepam (Zoletil[®]; Virbackorea, Republic of Korea), and 5.4 mg/kg tramadol hydrochloride (Tramadol HCl[®], Huons Inj.; Huons, Republic of Korea) using the same syringe. After tracheal intubation, anaesthesia was maintained using isoflurane (Forane[®]; JW Pharmaceutical, Republic of Korea), and 100% pure oxygen was supplied.

All surgical procedures were performed under aseptic conditions. An incision was made on the right forelimb, and the fracture site was fixed using a 10-mm diameter intramedullary (IM) pin

Sequencing of BMP7 peptide

```

1 MHVRSRLAAA PHSEVALWAP LFLRLSALAD FSLDNEVHSS FIHRRRLRSQE RREMQREILS
61 ILGLPHRPRP HLQ GKHNSAP MEMLDLYNAM AVEEGGGPGG QGFSYPYKAV FSTQGPPLAS
121 LQDSHFELTDA DMVMSFVNLV EHDKEFFHPR YHHRERFDL SKIPEGEAVT AAEFRIYKDY
181 IRERFDNETF RISVYQVLQE HLGRESDFEL LDSRTLWASE EGWLVDITA TSNHWVWNPR
241 HNLGLQLSVE TLDGQSINPK LAGLIGRHGP QNKQPEMVAE FKATEVHFERS IRSTGSKQRS
301 QNRSKTPKNQ EALRMANVAE NSSSDQRQAC KKHELYVSFR DLGWQDWIIA PEGYAAYYCE
361 GECAPPLNSY MNATNHAIYQ TLVHFINPET VPKPCCAPTQ LNAISVLYFD DSSNVILKKY
421 RNMVVRACGC H
  
```

BFP-1 peptide
 MW:1679.85Da
 PI: 9.5
 Net Charge: pH7.0:1

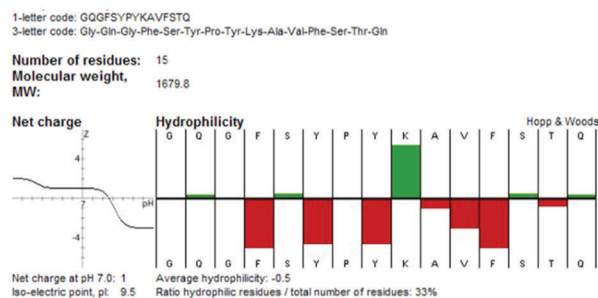


Figure 1. Characterisation of bone forming peptide (BFP-1). BFP-1 was synthesised by Fmoc solid-phase peptide synthesis using ASP48S and purified by reverse-phase high performance liquid chromatography with a Vydac Everst C18 column

doi: 10.17221/8445-VETMED

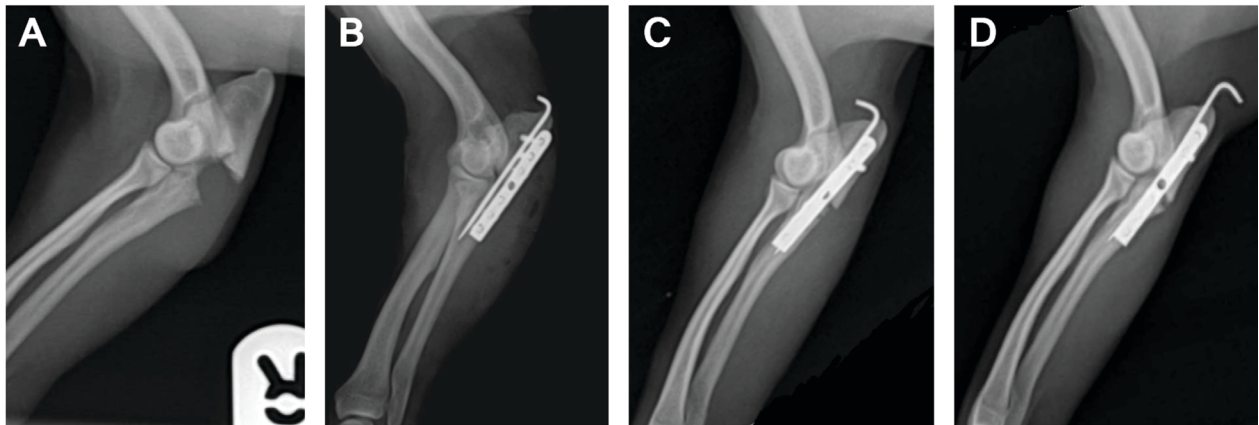


Figure 2. Radiographs of the right ulnar trochlear notch fracture. **A** – before the first surgery; **B** – immediately after the first surgery; **C** – two weeks after the first surgery; **D** – seventeen weeks after the first surgery

and a 2.0 miniplate and screws. One mg BFP-1 and Greenplast[®] fibrin glue (Greenplast kit; Green Cross Corp, Republic of Korea) were injected into the fracture site. Amoxicillin (20 mg/kg; Pamoxin[®]; Dong Wha Pharm, Republic of Korea) was administered postoperatively orally twice daily for seven days. Firocoxib (5 mg/kg; Previcox[®]; Merial, USA) was administered orally once per day for seven days. Post-operative radiographs were performed immediately, and at two and 17 weeks after the first surgery. The patient fell off of the bed presumably related to the blindness and was subsequently lame on her operated leg. A broken IM pin was observed on radiographs. A second surgery was performed, and the broken *i.m.* pin was removed. To encourage bone union, 100 µl of Matrigel (BD Matrigel[™] Basement Membrane Matrix, Becton Dickinson, USA) containing 3 mg BFP-1 was in-

jected into the fracture site. Radiographs were performed at 3, 8, 11, 16, 25, and 35 weeks after the second operation to monitor fracture healing. The fracture gap became narrower at three weeks after the second operation. At eight weeks after the second operation, a hard callus was observed at the cranial fracture line. Bone mineral density at the fracture site was increased at 16 weeks after the second operation. Fracture healing at 35 weeks was gradual compared with that observed on the previous radiograph.

DISCUSSION AND CONCLUSIONS

The rate of nonunion is 3.4% for all bone fractures in dogs (Millis and Jackson 2003). Nonunion occurs due to systemic diseases such as hormone disorders

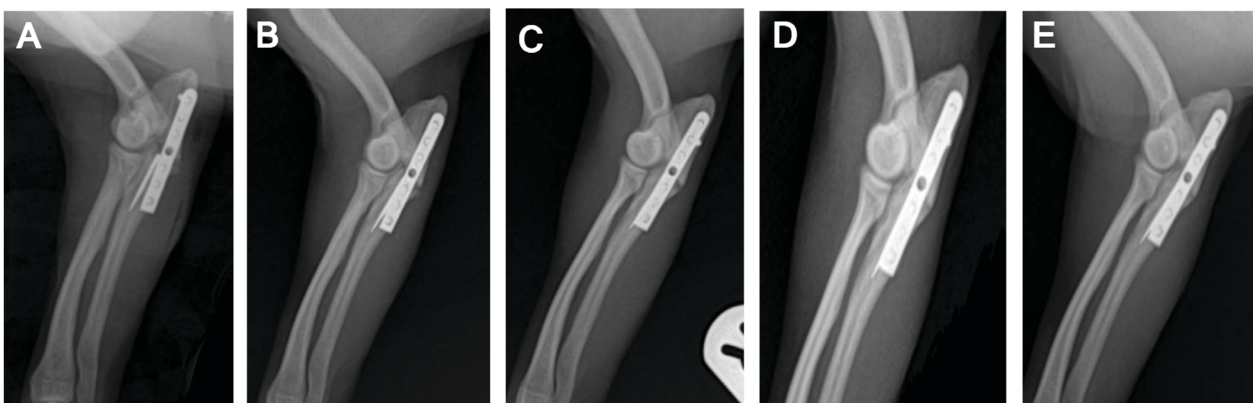


Figure 3. Radiographs after applying Matrigel containing 3 mg bone forming peptide (BFP-1) to the fracture site during the second surgery. **A** – immediately after the second surgery; **B** – three weeks after the second surgery; **C** – eight weeks after the second surgery; **D** – sixteen weeks after the second surgery; **E** – thirty-five weeks after the second surgery

and local issues such as poor fixation or impaired blood supply. Successful bone healing is achieved using local treatment agents that increase bone formation accompanied by systemic disease control. The current approach to bone healing focuses on the role of bone-forming molecules, proteins and cells. Several factors that increase bone formation, such as VEGF, PDGF, and BMPs, are available for treatment. Among these, the osteogenic efficacy of BMPs has been reported in many studies (Baltzer et al. 2012). We reported the osteogenic effect of recombinant human BMP-2 for delayed union in dogs (Kim et al. 2012b). In this study, we investigated a new peptide that has osteogenic activity similar to BMP-7. In this case, we chose BFP-1, derived synthetically from BMP-7, and which has bone regenerating efficacy. In particular, our previous *in vivo* study showed that BFP-1-pre-treated multipotent bone marrow stromal stem cell (MBSC)-transplanted animals had strongly increased bone formation compared to BMP-7-pre-treated MBSC-transplanted animals (Kim et al. 2012a).

In the present case, the dog was diagnosed with a right ulnar fracture and Cushing's disease. Cushing's disease results in delayed union or nonunion due to a negative balance between bone formation and bone resorption during bone remodeling (Norrdin et al. 1988). In this case, we speculated that Cushing's disease slowed bone healing. The broken IM pin was associated with falling off of the bed, however, the plate and screws were stable. Thus, we did not use additional implants during the second surgery; however, we increased the dose of BFP-1 and injected 3 mg BFP-1 and Matrigel to promote new bone formation and prevent nonunion. Matrigel is a basement membrane protein that forms into a three-dimensional gel at 37 °C. It has several growth factors such as transforming growth factor- β , fibroblast growth factor, epidermal growth factor, PDGF, and insulin-like growth factor, which promote bone formation (Kleinman and Martin 2005). In previous studies, we found that Matrigel enhanced new bone formation in a rat calvarial defect model (Kim et al. 2010). In the present study, a hard callus formed at the cranial fracture eight weeks after the second operation, and fracture healing was observed gradually over a 35 week period. These results suggest that the use of BFP-1 which is an immature form of the BMP-7-derived peptide, and

Matrigel encouraged bone regeneration. These results will have implications for osteogenesis and bone regeneration in veterinary medicine because BFP-1 is a better alternative to the BMPs from a financial point of view. Although additional studies are necessary to clarify osteogenic efficacy and side effects, this case identifies a new osteogenic stimulator that could be used in cases of non-union.

REFERENCES

- Baltzer AW, Ostapczuk MS, Stosch D, Granrath M (2012): The use of recombinant human bone morphogenetic protein-2 for the treatment of a delayed union following femoral neck open-wedge osteotomy. *Orthopedic Reviews* 4, 17–19.
- David L, Feige J-J, Bailly S (2009): Emerging role of bone morphogenetic proteins in angiogenesis. *Cytokine & Growth Factor Reviews* 20, 203–212.
- Kim SE, Shim KM, Kim SE, Choi SH, Bae CS, Han HJ, Kang SS (2010): Effect of matrigel for bone graft using hydroxyapatite/poly ϵ -caprolactone scaffold in a rat calvarial defect model. *Journal of Veterinary Clinics* 27, 325–329.
- Kim HK, Kim JH, Park DS, Park KS, Kang SS, Lee JS, Jeong MH, Yoon TR (2012a): Osteogenesis induced by a bone forming peptide from the prodomain region of BMP-7. *Biomaterials* 33, 7057–7063.
- Kim JK, Kim SE, Go AR, Kim SH, Shim KM, Bae CS, Choi SH, Kang SS (2012b): Clinical Application of Recombinant Human Bone Morphogenetic Protein-2 for Delayed Fractures in Dogs. *Journal of Veterinary Clinics* 29, 412–415.
- Kleinman HK, Martin GR (2005): Matrigel: Basement membrane matrix with biological activity. *Seminars in Cancer Biology* 15, 378–386.
- Mendicino SS, Rockett A, Wilber MR (1996): The use of bone grafts in the management of nonunions. *Journal of Foot and Ankle Surgery* 35, 452–457.
- Millis DL, Jackson AM (2003): Delayed Unions, Nonunions, and Malunions. In: Slatter DH (ed.): *Textbook of Small Animal Surgery*. 3rd ed. W.B. Saunders, Philadelphia. 1849–1861.
- Milovancev M, Muir P, Manley PA, Seeherman HJ, Schaefer S (2007): Clinical application of recombinant human bone morphogenetic protein-2 in 4 dogs. *Veterinary Surgery* 36, 132–140.
- Nandi S, Roy S, Mukherjee E, Kundu B, De D, Basu D (2010): Orthopaedic applications of bone graft & graft substi-

doi: 10.17221/8445-VETMED

tutes: a review. *Indian Journal of Medical Research* 132, 15–30.

Norrdin R, Carpenter T, Hamilton B, Brewster R (1988): Trabecular bone morphometry in beagles with hyperadrenocorticism and adrenal adenomas. *Veterinary Pathology Online* 25, 256–264.

Piermattei DL, Flo GL, DeCamp CE (2006): Delayed Union and Nonunion. In: Piermattei DL, Flo GL, DeCamp CE (eds.): *Brinker, Piermattei, and Flo's Handbook of Small Animal Orthopedics and Fracture Repair*. 4th ed. W.B. Saunders Elsevier, St. Louis. 168–176.

Received: 2014–05–26

Accepted after corrections: 2015–08–20

Corresponding Author:

Seong Soo Kang, Chonnam National University, College of Veterinary Medicine, Yongbong Dong, Bukgu, Gwangju, Republic of Korea; E-mail: vetkang@chonnam.ac.kr
