

## Hyperostotic tympanic bone spicules in domestic and wild animal species

A. HEITMANN<sup>1</sup>, B. PARZEFALL<sup>2</sup>, M. ZOLLNER<sup>3</sup>, A. BRUHSCHWEIN<sup>3</sup>,  
W. HERMANN<sup>1</sup>, A. BLUTKE<sup>1</sup>

<sup>1</sup>Institute of Veterinary Pathology at the Centre for Clinical Veterinary Medicine,  
Ludwig-Maximilians-University, Munich, Germany

<sup>2</sup>Royal Veterinary College, University of London, United Kingdom

<sup>3</sup>Clinic of Small Animal Surgery and Reproduction at the Centre for Clinical Veterinary  
Medicine, Ludwig-Maximilians-University, Munich, Germany

**ABSTRACT:** “Hyperostotic tympanic bone spicules” (HTBS), or “mucoperiosteal exostoses” (ME, syn.) are small, globular ( $\geq 1$  mm in diameter), mostly stalked and drumstick-like, bony structures, which arise from the inner wall of the tympanic bulla and project into the middle ear cavity. HTBS present as mineral densities inside the tympanic bulla on radiographs or computed tomographic (CT) images. They have previously been referred to as “otoliths” and were thought to represent mineral concretions secondary to otitis media. Recently, it was shown that HTBS actually consist of regularly composed bone tissue, covered by normal middle ear mucosa. So far, HTBS have only extensively been described in dogs, where they occur with a prevalence of up to > 45%. A recent study detected ME, most likely representing HTBS, in the tympanic cavities of skeletonised skull bones of African lions. To estimate the occurrence of HTBS in other mammal species, the middle ears of adult animals of 78 different domestic, wild, and zoo species undergoing routine necropsy at the Institute of Veterinary Pathology of the LMU Munich, Germany were examined in the present study. HTBS were found in the tympanic bullae of carnivorous species, such as canids (wolf, fox), and in several large felid species (lion, tiger, leopard, cheetah). In contrast, HTBS were not present in domestic cats (more than to 200 cases), small carnivorous species such as mustelids, nor in any primate, ungulate, ruminant, pig, insectivore, or rodent species. The detectability of HTBS by CT of the tympanic bullae of large felids was demonstrated in an African lion. Histologically, HTBS consisted of mature lamellar bone, covered by periosteum and a partially ciliated, flat epithelium, regularly without any apparent inflammatory alterations. The present study demonstrates that HTBS may frequently occur in large felids and in different canid species. These findings should be taken into account when examining the middle ear, or interpreting bulla radiographs/CT-images of the respective species. However, the factors triggering the development of HTBS remain to be identified.

**Keywords:** exostosis; middle ear; mucoperiosteum; otolith

Radiographic (Rx) or computed tomography (CT) evidence of radio-dense, round, up to several millimetres in diameter large, sessile objects in the tympanic bulla of dogs have long been referred to as “otoliths” (Farrow 1992; Ziemer et al. 2003). Otoliths were thought to represent mineral concretions in the tympanic cavity, supposedly resulting from otitis media (Ziemer et al. 2003). However, it was recently demonstrated that the vast majority of otolith-like structures are not dystrophic calcifica-

tions of necrotic debris of inflammatory origin, but are actually stalked, globular, bony, drumstick-like structures arising from the inner wall of the bulla tympanica and projecting into the middle ear cavity. These structures have been termed hyperostotic tympanic bone spicules (HTBS) (Parzefall et al. 2014). HTBS are composed of normally structured lamellar bone, covered by the normal middle ear mucoperiosteum. In dogs, the round “heads” of the HTBS reach dimensions of 1–6 mm in diameter,

being located on thin, bony stalks which can be as high as 14 mm. HTBS were reported to occur with a prevalence of more than 45% (Parzefall et al. 2014). HTBS preferentially occur in large breed dogs with high body weights, whereas no age or sex predilection was detected. In affected dogs, the average number of HTBS is ~ 3.0 (range: 1–8), occurring uni- or bilaterally (Parzefall et al. 2014). Using tympanic bulla CT scans with appropriate section thicknesses (~ 1 mm), HTBS can readily be identified in dogs without clinical evidence of middle ear disease (Parzefall et al. 2014). The (patho)-genesis, or probable function of HTBS is not yet clarified. In dogs, HTBS are almost exclusively located at the free margin of the remnant septum of the bullae, which incompletely divides the canine middle ear into the large caudoventral part of the tympanic bulla, the hypotympanum, and the smaller rostral epi- and mesotympanum, containing the tympanic membrane and the auditory ossicles. In nearly 100% of adult dogs, also small, needle-like tympanic bone spicules (STBS) arise from the free margin of the septum bulla, likely representing precursors of HTBS (Parzefall et al. 2014). Examination of HTBS revealed no reliable association with histopathological signs of middle ear inflammation. The factors triggering S/HTBS development therefore remain uncertain. Apart from dogs, little is known about the occurrence of HTBS in other mammalian species. A recent publication by Novales et al. (2015) reported the presence of “mucoperiosteal exostoses” (ME) in the middle ear cavities of African lions (*Panthera leo*). These ME presented as spiculated-to-globular, 2.1–16.5 mm large, sessile bony structures attached to the inner

wall of the tympanic bulla. Although the study by Novales et al. (2015) was not performed on fresh necropsy materials, but on skeletonised lion skull bones of an anatomical skull collection, the gross appearance and the histologic morphology of ME indicate that lion ME and canine HTBS indeed represent identical middle ear alterations (Parzefall et al. 2014; Novales et al. 2015).

To estimate the occurrence and the potential clinical relevance of HTBS in domestic, wild, and zoo (mammalian) species, and with the aim of characterising their gross, histological and ultrastructural appearance, the middle ears of various different mammal species were examined in the present study.

## MATERIAL AND METHODS

The middle ear cavities of adult animals of 78 different mammal species that underwent routine necropsy at the Institute of Veterinary Pathology of the Ludwig-Maximilians-University (LMU) Munich, Germany between 2012 and mid-2015 were macroscopically inspected for the presence of small tympanic bone spicules (STBS) of  $\leq 4$  mm length with needle-like, sharp, or clubbed tips of  $\leq 1$  mm in diameter, and for drumstick-like hyperostotic tympanic bone spicules (HTBS, Figure 1) with globular tip swellings of  $> 1$  mm in diameter (Parzefall et al. 2014). Additionally, skeletonised skulls (of 15 roe deer, 15 red foxes, one raccoon, and one badger) from anatomical collections (Institute of Veterinary Pathology, LMU) and from private hunting trophy collections were examined. If available, age, body weight, and sex were recorded in

Table 1. Species with hyperostotic tympanic bone spicules (HTBS)

Family	Species	Cases	Age <sup>a</sup>	HTBS/case	Prevalence <sup>b</sup>
Canidae	African wild dog ( <i>Lycan pictus</i> )	1	13	2	1/1
	Arctic wolf ( <i>Canis lupus arctos</i> )	1	2	4	1/1
	Gray wolf ( <i>Canis lupus</i> )	2	adult	2–3	2/2
	Maned wolf ( <i>Chrysocyon brachyurus</i> )	3	3–12	1	1/3
	Arctic fox ( <i>Vulpes lagopus</i> )	2	5–7	2	1/2
	Red fox ( <i>Vulpes vulpes</i> )	15	adult	1–4	4/15
Felidae	Siberian tiger ( <i>Panthera tigris altaica</i> )	2	15–17	8–12	2/2
	African lion ( <i>Panthera leo</i> )	4	2–19	2–9	4/4
	Persian leopard ( <i>Panthera pardus ciscaucasica</i> )	2	4–15	2–7	1/1
	Cheetah ( <i>Acinonyx jubatus</i> )	1	8	3	1/1

<sup>a</sup>age in years; <sup>b</sup>indicated as fraction of examined cases

doi: 10.17221/8819-VETMED

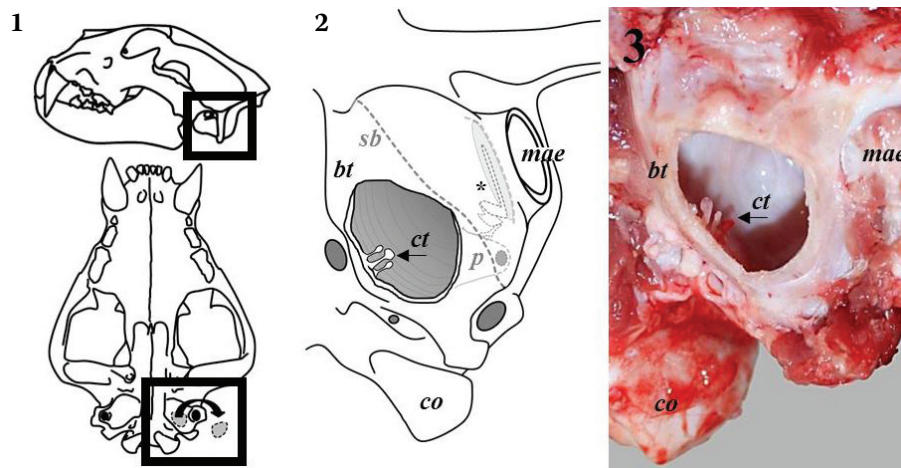


Figure 1. Location of hyperostotic tympanic bone spicules (HTBS) in the tympanic cavity (ct) of the middle ear (shown in a lion's skull as an example). **1**: Schematic illustration of a lion's skull (lateral aspect, 1-above; ventral aspect, 1-below). The ventral wall of the tympanic bulla is opened for visual inspection of the tympanic cavity (framed). **2**, **3**: Schematic illustration (**2**) and gross view (**3**) of the tympanic cavity (ct), after fenestration of the tympanic bulla (bt). In felids, a nearly complete bony septum (sb, indicated by a dotted line) separates the caudal part of the middle ear cavity, the tympanic bulla (ct, hypotympanum) and the meso- and epi-tympanum (\*), containing the tympanic membrane, and the auditory ossicles. Bony promontorium (p), surrounding the inner ear's cochlea. Left condylus occipitalis (co); outer ear canal (meatus acusticus externus, mae). Arrows: HTBS arising from the caudal wall of the tympanic bulla

each case. Only adult animals were included in the study. The species and the numbers of examined animals are shown in Tables 1 and 2. In species with well-developed tympanic bullae (e.g. felids, canids, mustelids, rodents, etc.) the ventral wall of the tympanic bulla was carefully removed for visual inspection of the tympanic cavity, using Liston forceps or an electric fraise, as previously described (Parzefall et al. 2009; Parzefall et al. 2014). In species without highly developed tympanic bullae (e.g. ungulates, pigs, ruminants) the middle ears were exposed following the external ear canal, using forceps and, where required, hammer and chisel. If present, the number, size, location and orientation of STBS and HTBS in the middle ear(s), as well as macroscopically visible signs of middle ear disease (abnormal infillings or inflammatory or neoplastic lesions) were recorded. Gross images were taken using a digital camera (D40, Nikon, Tokyo, Japan). For histopathology, samples of HTBS (one to six per case) including their "heads", stalks, the covering mucoperiosteum, and the adjacent tympanic wall from which the HTBS emerged, were taken from the middle ears of three African lions (*Panthera leo*), two Siberian tigers (*Panthera tigris altaica*), one Persian leopard (*Panthera pardus ciscaucasica*), one African wild dog (*Lycaon pictus*) and one Gray wolf (*Canis lupus*), with care in order

not to damage the mucoperiosteum. The samples were fixed in 4% neutral buffered formaldehyde solution at room temperature for  $\geq 24$  h, decalcified in an acid-based, slow decalcification agent (DC1, Labonord, Monchengladbach, Germany) for one to four days, as appropriate, routinely embedded in paraffin, sectioned at 3  $\mu$ m thickness and mounted on glass slides. The sections were routinely stained with haematoxylin and eosin (HE) and examined at  $\times 12.5$  to  $\times 400$  magnification. To demonstrate the three-dimensional ultrastructure of HTBS, formaldehyde-fixed samples of HTBS from a Siberian tiger were dehydrated following standard protocols, and scanning electron microscopy (SEM) was performed, using a digital scanning electron microscope (Zeiss DSM 950, Carl Zeiss AG, Oberkochen Germany). To demonstrate the detectability of HTBS by computed tomography (CT), a *post mortem* CT scan of the tympanic bulla of an African lion with a  $\sim 5 \times 1 \times 1$  mm sized, small HTBS was performed. After removal of the skull cap and the brain, the separated lion's head was placed in a ventral position, nose first in the gantry, and a helical 64-multislice CT unit (Somatom AS CT scanner, Siemens Medizintechnik, Erlangen, Germany) was used with the following scanning parameters: pitch 0.55, 140 mA, 120 kVp, rotation time 1 s, slice thickness 0.6 mm.

Table 2. Species in which hyperostotic tympanic bone spicules (HTBS) were not detected

Order	Family	Species	Cases
Primates	Cercopithecidae	Hamadryas baboon ( <i>Papio hamadryas</i> )	5
		Mandrill ( <i>Mandrillus sphinx</i> )	5
	Cebidae	White-headed capuchin ( <i>Cebus capucinus</i> )	5
		Common squirrel monkey ( <i>Saimiri sciureus</i> )	2
	Callitrichidae	Cotton-top tamarin ( <i>Saguinus oedipus</i> )	5
Emperor tamarin ( <i>Saguinus imperator</i> )		1	
Carnivora	Felidae	Domestic cat ( <i>Felis silvestris catus</i> )	205
		Eurasian lynx ( <i>Lynx lynx</i> )	1
		Snow leopard ( <i>Panthera uncia</i> )	1
		Caracal ( <i>Caracal caracal</i> )	1
	Mustelidae	Ferret ( <i>Mustela putorius furo</i> )	7
		White breasted marten ( <i>Martes foina</i> )	12
		European badger ( <i>Meles meles</i> )	8
		Procyonidae	Raccoon ( <i>Procyon lotor</i> )
	Otariidae	California sea lion ( <i>Zalophus californianus</i> )	4
		South American sea lion ( <i>Otaria flavescens</i> )	2
	Phocidae	Harbor seal ( <i>Phoca vitulina</i> )	2
	Ursidae	European brown bear ( <i>Ursus arctos arctos</i> )	1
	Ailuridae	Red panda ( <i>Ailurus fulgens</i> )	1
	Hyaenidae	Spotted hyena ( <i>Crocuta crocuta</i> )	1
Herpestidae	Meerkat ( <i>Suricata suricatta</i> )	1	
Perissodactyla	Equidae	Domestic horse ( <i>Equus ferus caballus</i> )	> 50
		Zebra ( <i>Equus quagga</i> & <i>E. grevyi</i> )	6
		Donkey ( <i>Equus africanus asinus</i> )	4
	Rhinocerotidae	Square-lipped rhinoceros ( <i>Ceratotherium simum</i> )	1
	Tapiridae	South American tapir ( <i>Tapirus terrestris</i> )	1
Artiodactyla	Camelidae	Alpaca ( <i>Vicugna pacos</i> )	> 20
		Llama ( <i>Lama glama</i> )	5
		Bactrian camel ( <i>Camelus bactrianus</i> )	4
	Bovidae	Domestic goat ( <i>Capra hircus</i> )	> 30
		Domestic sheep ( <i>Ovis aries</i> )	> 30
		Cattle ( <i>Bos taurus</i> )	> 30
		Chamois ( <i>Rupicapra rupicapra</i> )	5
		Alpine ibex ( <i>Capra ibex</i> )	2
		Nyala ( <i>Nyala angasii</i> )	1
	Suidae	Domestic pig ( <i>Sus domestica</i> )	> 50
		Roe deer ( <i>Capreolus capreolus</i> )	15
		Reindeer ( <i>Rangifer tarandus</i> )	1
		Eurasian elk ( <i>Alces alces</i> )	5
Persian fallow deer ( <i>Dama dama mesopotamica</i> )		2	
Chital ( <i>Axis axis</i> )		1	
Red deer ( <i>Cervus elaphus</i> )		1	
Common muntjac ( <i>Muntiacus muntjak</i> )		1	
Giraffidae	Giraffe ( <i>Giraffa camelopardalis reticulata</i> and <i>Giraffa camelopardalis rothschildi</i> )	4	

doi: 10.17221/8819-VETMED

Table 2 to be continued

Order	Family	Species	Cases
Proboscidea	Elephantidae	Asian elephant ( <i>Elephas maximus</i> )	1
		African bush elephant ( <i>Loxodonta africana</i> )	1
Diprotodontia	Macropodidae	Agile wallaby ( <i>Macropus agilis</i> )	6
		Red kangaroo ( <i>Macropus rufus</i> )	5
Lagomorpha	Leporidae	European rabbit ( <i>Oryctolagus cuniculus</i> )	> 50
Eulipotyphla	Talpidae	European mole ( <i>Talpa europaea</i> )	16
	Erinaceidae	European hedgehog ( <i>Erinaceus europaeus</i> )	14
Rodentia	Muridae	House mouse ( <i>Mus musculus</i> )	> 50
		House rat ( <i>Rattus rattus</i> )	16
		Guinea pig ( <i>Cavia porcellus</i> )	> 50
	Caviidae	Patagonian Mara ( <i>Dolichotis patagonum</i> )	25
		Capybara ( <i>Hydrochoerus hydrochaeris</i> )	4
	Chinchillidae	Long-tailed chinchilla ( <i>Chinchilla lanigera</i> )	10
	Sciuridae	Red squirrel ( <i>Sciurus vulgaris</i> )	7
		Eastern chipmunk ( <i>Tamias striatus</i> )	2
	Castoridae	European beaver ( <i>Castor fiber</i> )	4
	Hystriidae	Crested porcupine ( <i>Hystrix cristata</i> )	2
Octodontidae	Degu ( <i>Octodon degus</i> )	2	
Myocastoridae	Nutria ( <i>Myocastor coypus</i> )	2	
Macroscelidea	Macroscelidea	Round-eared elephant shrew ( <i>Macroscelides proboscideus</i> )	1
Chiroptera	Vespertilionidae	Bats ( <i>Nyctalus leisleri</i> and <i>Nyctalus noctula</i> )	5

## RESULTS

Small and hyperostotic tympanic bone spicules (S/HTBS) were only detected in the middle ears of diverse large felids and different canid species. The numbers of HTBS ranged from 0–4/middle ear in comparably small animals such as foxes, up to 12 HTBS in an Siberian tiger (Table 1). The largest HTBS was found in the tympanic bulla of a Siberian tiger and reached a length of 14 mm and a diameter of ~ 6 mm. In all cases with HTBS, also a few (1–7) STBS were present. In contrast, STBS without simultaneous occurrence of HTBS were observed in six out of 15 examined Red foxes. In one African lion, one Maned wolf, and in two Red foxes, HTBS (1–2) occurred unilaterally. In large felids, STBS and HTBS were predominantly located at the caudo-ventro-medial parts of the tympanic bulla (Figures 1 and 2), with random orientation, and without any recognisable preferential direction of growth (e.g. according to gravity). In canid species, STBS and HTBS were mostly located at the free margin of the incomplete septum bullae, but some also emerged from other locations of the

tympanic bulla. Macroscopic evidence of middle ear inflammation, such as turbid fluid or pus in the middle ear cavity or conspicuous fibrous thickening of the auricular mucoperiosteum was not present in any of the cases with HTBS.

In a 0.6 mm slice thickness CT scan of the middle ear cavity of an African lion, a unilateral, ~ 5 × 1 × 1 mm small HTBS emerging from the dorsal wall of the tympanic bulla could unambiguously be identified as a radio-dense, clearly delimitable structure (Figure 2).

Histological and ultrastructural investigations confirmed that HTBS in all examined species consisted of regularly composed lamellar bone tissue, covered by normal middle ear mucoperiosteum, a vascularised connective tissue-rich periosteum and a mostly flat, partially ciliated epithelium (Figure 2). Except for a few scattered lymphocytes and focal, sporadic, low-grade increase in collagenous connective tissue in the mucoperiosteum, no evidence of distinct acute or chronic inflammatory alterations were present in histological and SEM samples of HTBS (Figure 2).

In contrast to large felids and canids, STBS or HTBS were not detected in the middle ear cavities of comparably smaller carnivorous animal spe-



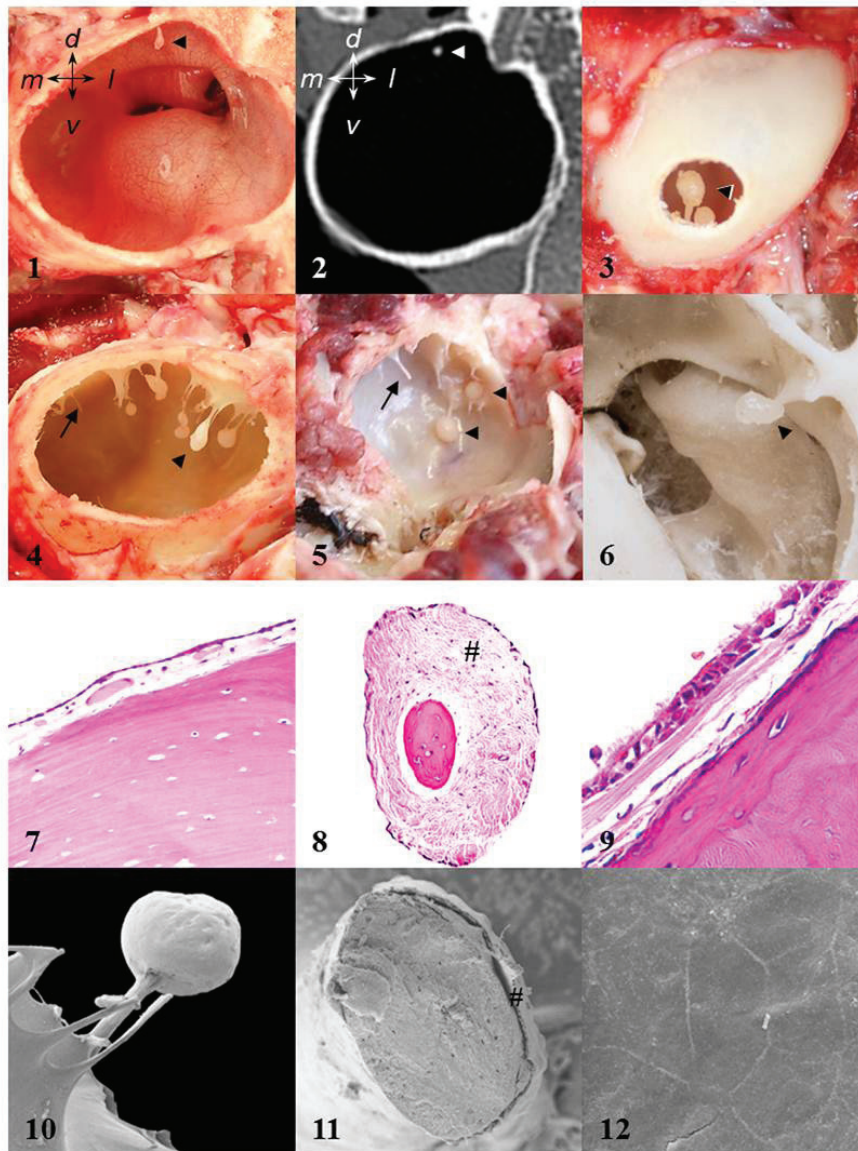


Figure 2. Gross view, computed tomography (CT), histology, and scanning electron microscopy (SEM) of Small Tympanic Bone Spicules (STBS, arrows) and Hyperostotic Tympanic Bone Spicules (HTBS, arrowheads). **1, 2:** Detectability of HTBS by CT. Anatomical directions are indicated. Dorsal (d), ventral (v), medial (m), lateral (l). **1:** Caudal aspect of the transversely sectioned right tympanic bulla of a 15-year old male African lion (*Panthera leo*) with a single, small (5 × 1 × 1 mm), club-shaped HTBS (arrowhead) emerging from the dorsal wall of the bulla. **2:** Corresponding CT-image (transverse section, bone window). The HTBS is clearly identifiable (arrowhead). **3–9:** Gross view (ventral aspect, **3–6**) of HTBS in the hypotympanic part of the tympanic bulla, HTBS-histology (**7–9**, decalcified paraffin sections, hematoxylin and eosin staining), and SEM of HTBS (**10–12**) in different carnivorous species: **3, 7:** Male, 15-year old Persian leopard (*Panthera pardus ciscaucasica*). **4:** Male, 10-year old African lion (*Panthera leo*). **5, 8, 9, 10–12:** Male, 17-year old Siberian tiger (*Panthera tigris*). **6:** Prepared skull bone of a female, adult Red fox (*Vulpes vulpes*). **7:** HTBS-head, composed of mature lamellar bone, covered by normal, vascularised mucoperiosteum. **8:** HTBS-stalk consisting of lamellar bone, surrounded by middle ear mucosa with abundant sub-epithelial connective tissue (#). **9:** Detail enlargement of the mucoperiosteal coverage of a HTBS-head, with a partially ciliated epithelium, and fine sub-epithelial connective tissue. **10–12:** SEM images of the surface of a HTBS head at low (× 14 magnification) (**10**), of (**11**) an (artificially) fractured HTBS-stalk (× 160 magnification), consisting of lamellar bone (note the multiple lacunae), covered by a flat epithelium and scant sub-epithelial connective tissue (#), and of the epithelial surface (**12**) of the HTBS-head (× 1000 magnification)

doi: 10.17221/8819-VETMED

cies, including domestic cats (more than 200 cases), mustelids and raccoons, or in any examined case of primate, pig, ruminant, ungulate, insectivore or rodent species. A complete list of all examined species, which includes species with only single examined cases in which no STBS and HTBS were detected, is provided in Table 2.

## DISCUSSION

Previous reports on HTBS (also known as “mucoperiosteal exostoses”, ME) reported their occurrence in dogs (Parzefall et al. 2014) and in African lions (Novales et al. 2015). The present study now demonstrates that HTBS also occur in a number of different other species. Interestingly, HTBS were only observed in individuals of carnivorous species, including large felids (Siberian tigers, Leopards, African lions, and a Cheetah), and canids (wolves, and, with lower prevalence, also foxes), but not in small carnivorous species such as domestic cats, ferrets, or martens, nor in species that anatomically do not possess a distinctly developed tympanic bulla (ruminants, ungulates and pigs), nor in primates, rodents, insectivores or leporids. Considering the limited numbers of animals available for examination in some species in the present study, the lack of S/HTBS does of course not exclude the possibility that S/HTBS could (less frequently) still occur in these species.

In dogs, hyperostotic tympanic bone spicules (HTBS) represent a common finding observed in ~ 20% of CT-scans of the tympanic bulla, and in up to ~ 45% of routine necropsy cases (Parzefall et al. 2014). In African lions (Novales et al. 2015) and in other large felid species, such as tigers and leopards (present study), HTBS also seem to occur frequently. Novales et al. (2015) showed that CT can be used to detect HTBS (ME) in the tympanic cavities of the skeletonised skull bones of African lions. In the present study, it was demonstrated that even a comparably small ( $5 \times 1 \times 1$  mm) HTBS in the tympanic bulla of a necropsied (fresh) African lion can clearly be identified by CT, using an appropriate CT-section thickness (0.6 mm).

Before the morphology of HTBS in dogs (Parzefall et al. 2014), and in African lions (Novales et al. 2015) was characterised in detail, HTBS detected by CT or radiography have frequently been misdiagnosed as dystrophic mineralisations of necrotic debris, so-called “otoliths”, that were presumed to have devel-

oped secondary to otitis media (Ziemer et al. 2003). In the previously published studies on HTBS in dogs (Parzefall et al. 2014) and in lions (Novales et al. 2015), as well as in the histopathologically and ultrastructurally examined cases in the present study, HTBS uniformly consisted of mature lamellar bone, and not of dystrophic calcification of necrotic tissue debris. Therefore, evidence of HTBS in radiographic/CT images of the respective species should be recognised as an important differential diagnosis to (rare) true dystrophic calcifications in the middle ear cavity, especially, if no other concomitant evidence of middle ear disease, as infilling of the tympanic cavity, irregular thickening of the bulla wall, or osteolytic alteration, is present.

In dogs, the morphological transition of sharp-tipped, needle-like, small tympanic bone spicules (STBS), to STBS with clubbed tips, and to drumstick-like HTBS indicates that HTBS develop from STBS (Parzefall et al. 2014). In the present study, STBS were also consistently observed in all cases of large felid and canid species, where HTBS were present. However, apart from their formal morphogenesis, the factors that determine development of HTBS in different species remain unclear.

Chronic otitis media has previously been suspected as a likely cause for formation of ME (HTBS) in lions (Novales et al. 2015), although this study was performed in skeletonised skull bones, so that soft tissue changes associated with ME could not be determined. A possible inflammatory pathogenesis was also discussed for canine HTBS (Parzefall et al. 2014), and such an aetiology could also be proposed for HTBS in the different species of canids and large felids examined in the present study. In cats, a recent histopathological study of the middle ear reported a high prevalence (48%) of mostly mild-to-moderate histological signs of otitis media in this species. In a high percentage (34%) of cases, histological signs of middle ear disease, such as proteinaceous fluid, infiltration of the mucoperiosteum by inflammatory cells, presence of cholesterol clefts, fibrin, granulation tissue, fibrosis and bony proliferation/osteolysis, were observed in macroscopically normal middle ears (Sula et al. 2014). If a similarly high prevalence of (chronic) otitis media might be assumed for other species, such as canids and large felids, an altered inflammatory milieu in the middle ear during chronic otitis media might be responsible for inducing/promoting the focal growth of S/HTBS in the tympanic cavity. HTBS

could then represent the remnants of a chronic otitis media in the tympanic cavity, even after the active inflammation is largely healed (Parzefall et al. 2014). However, this theory is speculative, since no data concerning the prevalence of histological signs of inflammation in the middle ear of different large felids or of canid species, including domestic dogs, with and without previous acute and/or chronic otitis media are available yet. In the present study, the focus was on the morphological characterisation of HTBS in diverse species. Accordingly, only specimens of HTBS were subjected to histopathological examination. Although histopathological findings compatible with mild/chronic otitis media, such as scant mucoperiosteal lymphocyte infiltration and fibrosis were sporadically present in these specimens, these rather unspecific lesions are *per se* not sufficient to directly prove an inflammatory pathogenesis of HTBS, since HTBS might have developed prior to, and independent of otitis media. *Vice versa*, the presence of HTBS without coinciding histopathological evidence of inflammation does not rule out an inflammatory pathogenesis of HTBS, since HTBS could also have developed as a consequence of a middle ear inflammation, which might no longer be present at the time when HTBS are examined histologically. Last but not least, the inflammatory alterations might be situated in a different location of the middle ear, and might therefore not be represented in a histological section of the HTBS. Despite the high prevalence of mild-to-moderate inflammatory alterations related to otitis media reported in domestic cats (Sula et al. 2014), macroscopically evident S/HTBS were not present in any of the more than 200 cats examined in the present study. Therefore, even if a similarly high prevalence of (chronic) inflammatory middle ear alterations might be present in other species such as dogs, other canid species and large felids, the findings of the present study show that there is also evidence for additional, species-specific factors involved in HTBS development. However, at present, we can only speculate as to the nature of these possible factors. The formation of HTBS related to otitis media might represent a species-specific reaction pattern of the auricular mucoperiosteum

to inflammatory stimuli, which is not common in other species. This reaction pattern could probably be related to distinct anatomical properties of the tympanic bullae in different carnivorous species. We have previously demonstrated that the occurrence of S/HTBS in dogs is positively correlated with body weight, but not with age or gender (Parzefall et al. 2014). However, due to the low number of available cases per species, comparable correlation analyses of age, body weight, or tympanic bullae volumes with the occurrence of HTBS were not feasible in the present study. Therefore, further studies with detailed histopathological examinations of different standardised middle ear regions and adequate scoring of findings compatible with acute/chronic middle ear inflammation in larger numbers of cases per species, each including animals with and without HTBS, are needed to elucidate the pathogenesis of HTBS.

## REFERENCES

- Farrow CS (1992): Known case conference. *Veterinary Radiology and Ultrasound* 33, 262–272.
- Novales M, Ginel PJ, Diz A, Blanco B, Zafra R, Guerra R, Mozos E (2015): Mucoperiosteal exostoses in the tympanic bulla of African lions (*Panthera leo*). *Veterinary Pathology* 52, 377–383.
- Parzefall B, Schmahl W, Blutke A, Baiker K, Matiassek K (2009): A rapid approach to ultrastructural evaluation and DNA analysis of the vestibular labyrinth and ganglion in dogs and cats. *Journal of Neuroscience Methods* 177, 217–224.
- Parzefall B, Rieger A, Volk HA, Maierl J, Bruhschwein A, Blutke A (2014): Prevalence and characterization of small tympanic bone spicules and drumstick-like hyperostotic tympanic bone spicules in the middle ear cavity of dogs. *Veterinary Radiology and Ultrasound* 56, 25–32.
- Sula MM, Njaa BL, Payton ME (2014): Histologic characterization of the cat middle ear: in sickness and in health. *Veterinary Pathology* 51, 951–967.
- Ziemer LS, Schwarz T, Sullivan M (2003): Otolithiasis in three dogs. *Veterinary Radiology and Ultrasound* 44, 28–31.

Received: 2015–01–15

Accepted after corrections: 2016–02–18

Corresponding Author:

Andreas Blutke, Ludwig-Maximilians-University (LMU), Institute of Veterinary Pathology at the Centre for Clinical Veterinary Medicine, Munich, Germany.

E-mail: blutke@patho.vetmed.uni-muenchen.de