

## Ultrasonographic measurements of abdominal lymph nodes in growing puppies

M. PUGLIESE<sup>1</sup>, A. LA PIETRA<sup>1</sup>, L. LIOTTA<sup>1</sup>, F. MACRÌ<sup>1</sup>, A. PALUMBO PICCIONELLO<sup>2</sup>, M. DE MAJO<sup>1</sup>

<sup>1</sup>Department of Veterinary Science, University of Messina, Messina, Italy

<sup>2</sup>School of Veterinary Medical Sciences, University of Camerino, Matelica, Macerata, Italy

**ABSTRACT:** The sonographic appearance of the normal abdominal lymph nodes in adult dogs has been well described, but the data in puppies are scarce and of poor quality. The aim of the current study was to evaluate any differences in abdominal lymph node sonographic measurements in puppies of various sizes and to determine whether any differences were correlated with growth and weight gain during the first 10 weeks of life. By an approach based on prospective and serial measurements, length, width and thickness of jejunal, medial iliac and hypogastric nodes were obtained in twenty-one healthy puppies of various sizes, at six (T0), eight (T1) and ten (T2) weeks of age. The relationship between body weight and length, width and thickness of lymph nodes was evaluated using a Pearson correlation analysis. An ANOVA test was used to compare the measurements at different ages. Jejunal and iliac lymph nodes were the largest in large breed dogs. In large-sized puppies only the length of the jejunal lymph nodes correlated positively with width and body weight. Length of medial iliac lymph nodes correlated positively with width and body weight in all three sizes. None of the measurements of hypogastric lymph nodes were related to body weight. In large-sized puppies jejunal and iliac lymph nodes increased in length and width with age; in medium-sized puppies only iliac lymph nodes increased; in small-sized puppies jejunal and iliac lymph nodes significantly decreased in length and thickness. In conclusion, the lymph node sizes in young animals are directly related to body weight and do not decrease with growth during the first 10 weeks of life, except in small-sized puppies.

**Keywords:** abdominal lymph nodes; puppies; size; measurements; ultrasonography

Ultrasonography is currently considered as the first step in the imaging assessment of abdominal lymph nodes, and with the availability of high-resolution probes, evaluations of the sonographic features of deep lymph nodes have become increasingly precise. Parietal and visceral lymph nodes can be identified in the abdomen: the parietal group includes the lumbar, aortic, renal, medial iliac, hypogastric, sacral and inguinal nodes; the visceral group includes the hepatic, splenic, gastric, pancreatic-duodenal, jejunal and colic lymph nodes (Pugh 1994).

The ultrasonographic appearance and size of normal abdominal lymph nodes in adult dogs has been previously described (Llabrez-Diaz 2004; Nyman et al. 2005; Mayer et al. 2010). Recently, data regarding the size of the jejunal and medial iliac lymph nodes

in healthy puppies were also provided (Stander et al. 2010; Krol and O'Brien 2012). Our purpose was to evaluate, by an approach based on prospective and serial measurements, whether there were any differences in measurements of abdominal lymph nodes in puppies of various sizes and whether any differences were correlated with growth and weight gain.

### MATERIAL AND METHODS

Twenty-one healthy puppies of various sizes were evaluated: large-sized ( $n = 7$ , Anatolian Shepherd dogs), medium-sized ( $n = 7$ , English Setters) and small-sized ( $n = 7$ , Jack Russell Terriers). The subjects of each breed originated from two different litters. The same puppies were examined at six

(T0), eight (T1) and ten (T2) weeks of age, and body weight was registered at those times. Inclusion criteria were good health and no symptoms of gastrointestinal disease, normal haematological profile; evidence of systemic abnormalities for at least seven days before, during or two weeks after the study constituted an exclusion criterion. Moreover, a strict deworming schedule was followed. All treatments, housing and animal care reported were carried out in accordance with the EU Directive 2010/63/EU for animal experiments. The pet owners consented to have their animals involved in this study. All of the subjects were fasted for a minimum of 4 h and examined without chemical restraint by one observer (A.L.P.) using a Mylab 40Vet (Esaote, Italy) with a microconvex (5–8 MHz) or linear transducer (7.5–12 MHz). Gain and depth were adjusted and registered for optimal image quality in similar-sized puppies. The hair over the abdomen was not clipped, and the use of isopropyl alcohol (70%) allowed good-quality images. With the dogs in dorsal recumbency, the jejunal lymph nodes were identified alongside the cranial mesenteric artery and vein. The medial iliac and hypogastric lymph nodes were imaged with the dogs in lateral recumbency, the first near the bifurcation of the aorta and external iliac artery and the second between the internal iliac and median sacral arteries. The scanning plane was then adjusted for optimal visualisation of the lymph nodes in their long axis (sagittal plane) to evaluate the maximum length and thickness; following examination in the long axis, the transducer was rotated 90° to measure the lymph node maximum width in the short axis (dorsal plane), as shown in Figure 1. The average values of three consecutive measurements were expressed in centimetres (cm). Regarding the jejunal lymph nodes, the measurements were performed on the largest lymph node. Data were analysed using Proc GLM SAS (2001) by applying an ANOVA with repeated measurements considering the size of lymph nodes (length, width, thickness) as a dependent variable, according to the following model:

$$Y_{ijk} = \mu + (\alpha\beta)_{ij} + \varepsilon_{ijk}$$

where:

$Y_{ijk}$  = the dependent variable

$\mu$  = the general mean

$\alpha$  = the independent variable age ( $i = 6, 8, 10$  weeks)

$\beta$  = the independent variable lymph nodes ( $j = \text{left, right}$ )

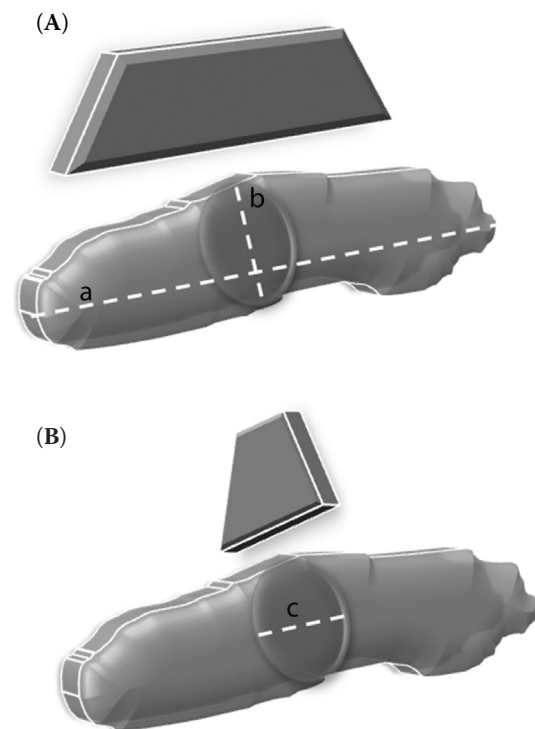


Figure 1. Planes of the lymph nodes used to obtain measurements: (A) sagittal plane for maximum length (a) and thickness (b); (B) dorsal plane for maximum width (c) in the short axis

Relationships between body weight and the length, width and thickness of lymph nodes were investigated using Pearson correlation analysis. Statistical significance was set at the  $P < 0.05$  level.

## RESULTS

One hundred and fifteen lymph nodes were measured. Fifteen (71%) jejunal lymph nodes had a vermiform shape and six (29%) a miscellaneous shape. The medial iliac lymph nodes commonly appeared ovoid (85%) and the hypogastric lymph nodes also appeared ovoid (74%). All lymph nodes appeared uniformly hypoechoic or with a hyperechoic centre. Jejunal and iliac lymph nodes were the largest in large breed dogs.

Table 1 reports the correlations between length, width, thickness and weight gain in the puppies of large size. It was noted that the length of the jejunal lymph node correlated positively ( $P < 0.01$ ) with the width and body weight. The length of the iliac lymph node also correlated positively with the width ( $P < 0.05$ ) and body weight ( $P < 0.01$ ). The length of the hypogastric lymph node correlated

doi: 10.17221/216/2015-VETMED

Table 1. Pearson correlation coefficients amongst length (cm), width (cm), thickness (cm) of jejunal, medial iliac and hypogastric lymph nodes and body weight (kg) in large, medium and small sized puppies

	Jejunal				Medial iliac				Hypogastric			
	length	width	thick-ness	body weight	length	width	thick-ness	body weight	length	width	thick-ness	body weight
<b>Large sized puppies</b>												
Length	1.00	0.68***	0.17	0.77***	1.00	0.33*	0.18	0.58***	1.00	0.34*	0.21	0.02
Width	–	1.00	0.25	0.39	–	1.00	0.16	0.44**	–	1.00	0.42***	–0.06
Thickness	–	–	1.00	0.21	–	–	1.00	0.23	–	–	1.00	–0.19
Body weight	–	–	–	1.00	–	–	–	1.00	–	–	–	1.00
<b>Medium sized puppies</b>												
Length	1.00	0.46*	0.53**	0.21	1.00	0.57***	0.15	0.40**	1.00	0.09	0.25*	0.23
Width	–	1.00	0.50**	0.11	–	1.00	0.17	0.32*	–	1.00	0.15	–0.27*
Thickness	–	–	1.00	0.01	–	–	1.00	0.01	–	–	1.00	0.09
Body weight	–	–	–	1.00	–	–	–	1.00	–	–	–	1.00
<b>Small sized puppies</b>												
Length	1.00	–0.18	0.56**	–0.11	1.00	0.38*	0.12	0.41**	1.00	0.41**	0.43**	–0.13
Width	–	1.00	0.10	0.42*	–	1.00	0.48**	0.11	–	1.00	0.52***	–0.14
Thickness	–	–	1.00	0.20	–	–	1.00	–0.06	–	–	1.00	–0.02
Body weight	–	–	–	1.00	–	–	–	1.00	–	–	–	1.00

\*, \*\*, \*\*\* significant at the  $P \leq 0.05$ , 0.01 and 0.001 levels, respectively

positively with the width ( $P < 0.05$ ) and thickness ( $P < 0.01$ ). None of the measurements of this node were related to the body weight.

Table 1 reports the correlations between length, width, thickness and weight gain in the puppies of medium size. In jejunal lymph nodes, the length and width were directly related ( $P < 0.05$ ), as were length and thickness and width and thickness ( $P < 0.01$ ). The average length of the iliac lymph nodes correlated positively with the width ( $P < 0.01$ ) and body weight ( $P < 0.01$ ); the width was also directly related to body weight ( $P < 0.05$ ). Finally, the length of the hypogastric lymph node was correlated with thickness ( $P < 0.05$ ), but the width was negatively correlated with body weight ( $P < 0.05$ ).

Table 1 reports the correlations between length, width, thickness and weight gain in the puppies of small size. The length of the jejunal lymph node was positively correlated with thickness ( $P < 0.01$ ), and the width was related to body weight ( $P < 0.05$ ). The length of the medial iliac lymph node was correlated with width ( $P < 0.05$ ) and body weight ( $P < 0.01$ ), as were the width and thickness ( $P < 0.01$ ). The length of the hypogastric lymph node was related to both width and thickness ( $P < 0.01$ ), while the width was strongly correlated to the thickness ( $P < 0.01$ ).

Significant results from serial time examinations are reported in Table 2. In large size puppies, it appeared that the jejunal lymph nodes grew in length after four weeks (T2) compared to the first measurement (T0) (mean values 3.94 cm vs. 4.74 cm;  $P < 0.05$ ). The right medial iliac lymph nodes increased in length at T1 (2.20 cm vs. 2.64 cm;  $P < 0.05$ ), while the left medial iliac lymph nodes increased in length (2.48 cm vs. 3.09 cm;  $P < 0.01$ ) and width (0.45 cm vs. 0.64 cm;  $P < 0.01$ ) at T2. The right hypogastric lymph node decreased significantly in width (0.29 cm vs. 0.23 cm;  $P < 0.05$ ) and thickness (0.47 cm vs. 0.35 cm;  $P < 0.01$ ) at T2.

In the medium size group, the jejunal lymph node did not change during the period of evaluation. The medial iliac lymph nodes increased significantly at T1 and T2. The length (1.99 cm vs. 2.68 cm;  $P < 0.01$ ) and width (0.37 cm vs. 0.49 cm;  $P < 0.01$ ) of the right medial iliac lymph node increased significantly at T1 and at T2. The length (2.26 cm vs. 2.79 cm;  $P < 0.05$ ) and width (0.40 cm vs. 0.51 cm;  $P < 0.01$ ) of the left medial iliac lymph node increased significantly at T2.

In small-sized puppies, it emerged that the length of the jejunal lymph nodes decreases significantly at T2 (2.84 cm vs. 2.60 cm;  $P < 0.05$ ). The only difference detected in the medial iliac lymph nodes was

Table 2. Trend of significant variation of measurements of different lymph nodes in puppies of all sizes in relation to the examination time; means values expressed in cm  $\pm$  SD; six (T0), eight (T1) and ten (T2) weeks of age

Size	Node	Measurement	T0	T1	T2
Large breed	jejunal	length	3.94 $\pm$ 0.56 <sup>a</sup>	4.55 $\pm$ 0.71 <sup>ac</sup>	4.74 $\pm$ 0.62 <sup>bc</sup>
		right length	2.20 $\pm$ 0.18 <sup>a</sup>	2.64 $\pm$ 0.40 <sup>b</sup>	2.78 $\pm$ 0.09 <sup>b</sup>
	iliac	left length	2.48 $\pm$ 0.37 <sup>A</sup>	2.65 $\pm$ 0.37 <sup>A</sup>	3.09 $\pm$ 0.58 <sup>B</sup>
		left width	0.45 $\pm$ 0.06 <sup>A</sup>	0.53 $\pm$ 0.12 <sup>AC</sup>	0.64 $\pm$ 0.11 <sup>BC</sup>
	hypogastric	right width	0.29 $\pm$ 0.05 <sup>a</sup>	0.25 $\pm$ 0.04 <sup>ac</sup>	0.23 $\pm$ 0.05 <sup>bc</sup>
		right thickness	0.47 $\pm$ 0.08 <sup>A</sup>	0.25 $\pm$ 0.05 <sup>B</sup>	0.35 $\pm$ 0.07 <sup>B</sup>
Medium breed	iliac	right length	1.99 $\pm$ 0.52 <sup>a</sup>	2.49 $\pm$ 0.36 <sup>b</sup>	2.68 $\pm$ 0.37 <sup>B</sup>
		left length	2.26 $\pm$ 0.62 <sup>a</sup>	2.62 $\pm$ 0.47 <sup>ac</sup>	2.79 $\pm$ 0.31 <sup>bc</sup>
		right width	0.37 $\pm$ 0.08 <sup>a</sup>	0.47 $\pm$ 0.08 <sup>b</sup>	0.49 $\pm$ 0.08 <sup>B</sup>
		left width	0.40 $\pm$ 0.10 <sup>a</sup>	0.45 $\pm$ 0.07 <sup>a</sup>	0.51 $\pm$ 0.09 <sup>B</sup>
		length	2.84 $\pm$ 0.65 <sup>a</sup>	3.15 $\pm$ 0.39 <sup>a</sup>	2.60 $\pm$ 0.44 <sup>ab</sup>
Small breed	jejunal	length	2.84 $\pm$ 0.65 <sup>a</sup>	3.15 $\pm$ 0.39 <sup>a</sup>	2.60 $\pm$ 0.44 <sup>ab</sup>
		iliac	left thickness	0.35 $\pm$ 0.14 <sup>A</sup>	0.51 $\pm$ 0.06 <sup>B</sup>
	hypogastric	left length	0.78 $\pm$ 0.11 <sup>a</sup>	0.81 $\pm$ 0.09 <sup>ac</sup>	0.92 $\pm$ 0.07 <sup>bc</sup>
		right thickness	0.31 $\pm$ 0.04 <sup>a</sup>	0.40 $\pm$ 0.08 <sup>bc</sup>	0.33 $\pm$ 0.07 <sup>ac</sup>
		left thickness	0.28 $\pm$ 0.14 <sup>a</sup>	0.37 $\pm$ 0.03 <sup>bc</sup>	0.36 $\pm$ 0.05 <sup>ac</sup>

<sup>a-b</sup> means in the same row with different superscripts are significant at  $P \leq 0.05$

<sup>A-C</sup> means in the same row with different superscripts are significant at  $P \leq 0.01$

the thickness of the left node, which significantly increased at T1 (0.35 cm vs. 0.51 cm;  $P < 0.01$ ) and decreased at T2 (0.51 cm vs. 0.36 cm;  $P < 0.01$ ). The length of the left hypogastric lymph node increased significantly at T2 (0.78 cm vs. 0.92 cm;  $P < 0.05$ ). The thickness of the right hypogastric lymph nodes increased at T1 (0.31 cm vs. 0.40 cm;  $P < 0.05$ ) and decreased at T2 (0.40 cm vs. 0.33 cm;  $P < 0.05$ ). The thickness of the left nodes increased at T1 (0.28 cm vs. 0.37 cm;  $P < 0.05$ ).

## DISCUSSION

Various factors, such as breed, body weight, genetics and antigenic stimuli, may influence lymph node size in puppies. In puppies the lymph nodes are easily detectable. In this study, jejunal lymph nodes showed mainly a vermiform shape; the medial iliac lymph nodes commonly appeared ovoid and the hypogastric lymph nodes also appeared ovoid. The shape and echogenicity of lymph nodes were similar to those reported in other studies (Mayer et al. 2010; Krol and O'Brien 2012).

The size of lymph nodes may be influenced by the position of the patient and by the scanning plane. For this reason we used a standard approach: dorsal re-

cumbency for jejunal lymph nodes and lateral recumbency for medial iliac and hypogastric lymph nodes. In this study, we used one transverse measurement on the short axis image (width) and two measurements on the long axis image (length and thickness). In contrast to previous studies (Agthe et al. 2009), the width and thickness of jejunal lymph nodes were not directly related to growth in any of the sizes evaluated; rather, we found that the length of the jejunal lymph node was directly related to growth in large breed dogs and decreased in small breed dogs only. However, in that study, length was not measured, and the dogs belonged to a variety of breeds and were aged between six months and 14 years.

The length and thickness of medial iliac lymph nodes reported in our study are greater than those reported in previous studies in puppies of 4–6 weeks (Krol and O'Brien 2012) and in adult dogs (Mayer et al. 2010); also, the length and the width of these lymph nodes were directly related to growth. Jejunal and iliac lymph nodes were the largest in large breed dogs. This has also been reported in one previous study, which considered only the length of the jejunal and medial iliac lymph nodes in relation to breed (Krol and O'Brien 2012).

In another study, researchers found no significant differences regarding the width of iliac lymph nodes

doi: 10.17221/216/2015-VETMED

compared to the breed, but their results considered only one measurement of the nodes (Mayer et al. 2010). During the time interval of evaluation, we found an increase in length of jejunal nodes in large-sized puppies and dimensions of iliac lymph nodes directly correlated with body weight in puppies of all three sizes. This is similar to previous studies of jejunal lymph nodes (Agthe et al. 2009) and retropharyngeal lymph nodes (Burns et al. 2008) but it is in contrast with other data (Stander et al. 2010). It must be emphasised that these authors took only one measurement (thickness). In the three groups examined no statistical correlation was detected between body weight and dimensions of hypogastric lymph nodes. The dimensions of hypogastric lymph nodes decreased during serial controls. No data on dimensions were reported for these lymph nodes in puppies.

One limitation of this study is the relatively short period of observation (30 days), while the serial control methodology is more statistically reliable than a single evaluation. We have not statistically analysed the data obtained to compare the puppies from different litters of the same breed, but some authors (Krol and O'Brien 2012) have proposed the evaluation of lymph node measurements in relation to environmental variables linked to the bitch and the puppies.

In conclusion, the lengths of the medial iliac lymph nodes that we describe here in puppies are greater than previously described by others. Also, we show that lymph node sizes in very young animals do not decrease with age, except in small size puppies, and are directly related to body weight. Only the hypogastric lymph node showed a decrease in dimensions during growth without correlation with body weight.

## REFERENCES

- Agthe P, Caine AR, Posch B, Herrtage ME (2009): Ultrasonographic appearance of jejunal lymph nodes in dogs without clinical signs of gastrointestinal disease. *Veterinary Radiology and Ultrasound* 50, 195–200.
- Burns GO, Scrivani PV, Thompson MS, Erb HN (2008): Relation between age, body weight, and medial retropharyngeal lymph node size in apparently healthy dogs. *Veterinary Radiology and Ultrasound* 49, 277–281.
- Krol L, O'Brien R (2012): Ultrasonographic assessment of abdominal lymph nodes in puppies. *Veterinary Radiology and Ultrasound* 53, 455–458.
- Llabrez-Diaz F (2004): Ultrasonography of the medial iliac lymph nodes in the dog. *Veterinary Radiology and Ultrasound* 45, 156–165.
- Mayer MN, Lawson JA, Silver TI (2010): Sonographic characteristics of presumptively normal canine medial iliac and superficial inguinal lymph nodes. *Veterinary Radiology and Ultrasound* 51, 638–641.
- Nyman HT, Kristensen AT, Skovgaard IM, McEvoy FJ (2005): Characterization of normal and abnormal canine superficial lymph nodes using gray scale B-mode, color flow mapping, power and spectral Doppler ultrasonography, a multivariate study. *Veterinary Radiology and Ultrasound* 46, 404–410.
- Pugh CR (1994): Ultrasonographic examination of abdominal lymph nodes in the dog. *Veterinary Radiology and Ultrasound* 35, 110–115.
- SAS (2001): User's Guide, ver. 8.1. SAS Institute, Inc., Cary, NC, USA.
- Stander N, Wagner WM, Goddard A, Kirberger RM (2010): Normal canine pediatric gastrointestinal ultrasonography. *Veterinary Radiology and Ultrasound* 51, 75–78.

Received: 2015–09–04

Accepted after corrections: 2016–05–06

Corresponding Author:

Francesco Macrì, University of Messina, Department of Veterinary Science, Polo Universitario Annunziata,  
98168 Messina, Italy  
E-mail: framac@alice.it