

Deslorelin treatment of hyperoestrogenism in neutered ferrets (*Mustela putorius furo*): a case report

A. PROHACZIK, M. KULCSAR, GY. HUSZENICZA

Faculty of Veterinary Science, Szent Istvan University, Budapest, Hungary

ABSTRACT: Hyperoestrogenism causing progressive alopecia in neutered ferrets may be induced by ovarian remnant syndrome (ORS) and nodular hyperplasia of the adrenocortex (hyperadrenocorticism, NHA). The objective of the study was to determine whether a slow-release implant of a gonadotropin releasing hormone (GnRH) analogue, deslorelin, has any value in therapy of hyperoestrogenism of adrenocortical origin (NHA). Three supposed cases of NHA with alopecia and other clinical signs of hyperoestrogenism ($n = 2$ spayed females in oestrous and $n = 1$ castrated male) were treated with a subcutaneous implant of 4.7 mg deslorelin acetate. Blood samples were collected, and plasma levels of estradiol (E_2) were determined just before, and some weeks after treatment. For realistic monitoring, blood samples for E_2 determination were also taken from intact, healthy (untreated control) females after the beginning of heat ($n = 5$), or 9–21 days after, with hCG induced ovulation ($n = 6$), or out of breeding season ($n = 3$). Before treatment, all three alopecic ferrets showed elevated E_2 concentrations (99.45–139.9 pmol/l) similar to the untreated control females in oestrous (61.6–123.02 pmol/l) ($P = 0.229$). Some weeks after the deslorelin administration, the hair of these ferrets began to grow again and the elevated E_2 concentrations significantly decreased compared to the pre-treatment values ($P = 0.035$). E_2 concentrations reached the basal level (12.89–16.08 pmol/l) typical for that of the untreated control females in anoestrus or in luteal phase (12.0–30.58 pmol/l) ($P = 0.137$). All treated ferrets were examined again 19–21 months after implant insertion (the implant still being present) and all of them had normal hair and were clinically healthy. These observations prove that deslorelin can suppress the E_2 production of NHA, and is therefore a useful tool in the therapy of hormonal alopecia neutered ferrets.

Keywords: deslorelin; GnRH analogue; estradiol; hyperadrenocorticism

After gonadectomy, ferrets may show elevated E_2 concentrations principally as a result of reactivated ovarian remnants (females) and nodular hyperplasia of the adrenocortex in both genders (hyperadrenocorticism, NHA).

The pathophysiology of ovarian remnant syndrome (ORS) is well described in cats (DeNardo et al., 2001). In the abdominal cavity remaining ovarian cells may implant on the abdominal wall, omentum or around the ligature. After revascularization, these cells may reactivate and become steroidogenic. In the next breeding season following gonadectomy, they may behave as normal ovarian tissue, producing E_2 and with growing tertiary follicles. In ferrets, clinical signs include vulvar swelling (oestrous). If this condition lasts longer

than some weeks, ferrets are at risk of developing typical hormonal alopecia, and other consequences of E_2 hyperstimulation, such as bone marrow suppression.

Adrenocortical disease has been recognized for almost 20 years as a common disease affecting pet ferrets in the US and in European countries (Hillyer, 1992; Lipman et al., 1993; Rosenthal et al., 1993; Rosenthal, 1997; Weiss and Scott, 1997; Wheler and Kamieniecki, 1998; Weiss et al., 1999; Schoemaker et al., 2000, 2002, 2004; Wagner et al., 2001, 2005; Schoemaker, 2003; Bielinska et al., 2006). It has been supposed that competent cells in the ferret adrenal cortex undergo neoplastic transformation and adopt features of gonadal steroidogenic cells in response to the hormonal changes that follow

gonadectomy. These cells may be committed gonadal progenitors that are ectopically located in the adrenal gland or multipotential progenitors capable of differentiation into either adrenocortical or gonadal-like steroidogenic cells, depending on the hormonal milieu and other environmental factors (Patterson et al., 2003). Given the similarities between neoplastic adrenocortical cells and normal gonadal somatic cells, it comes as no surprise that reproductive hormones along with their receptors and intracellular effectors play prominent roles in adrenocortical tumourigenesis in ferrets (Bielinska et al., 2006). Several lines of evidence suggest that LH signaling plays a central role in adrenocortical tumourigenesis in neutered ferrets (Schoemaker et al., 2000; Schoemaker, 2003; Bielinska et al., 2006).

Clinical signs of hyperadrenocorticism include a range of cutaneous, reproductive, or behavioral symptoms, all related to the elevated concentrations of sexual steroids. Cutaneous signs are characterized by bilaterally symmetric alopecia beginning over the tail and progressing forward along the body. Sometimes pruritus may occur as well. Reproductive abnormalities (depending on which sex steroid is elevated) may include swelling of the vulva (oestrous) in females, and dysuria in males (Rosenthal and Peterson, 1996b; Coleman et al., 1998). Behavioral abnormalities may include increased mounting behavior or aggression in both genders, and marking behavior in males. Longstanding cases may show mild anemia and petechiation (as a result of the suppressive effect of E_2 on the bone marrow), muscle wasting, and other non-specific signs such as lethargy and posterior paresis.

In most cases, diagnosis is based on clinical signs. Complete blood counts and chemistry panels are within normal limits in the vast majority of animals, except in longstanding cases in which anemia or decreased platelet numbers may be seen. As the elevated hormone in hyperadrenocorticism may be one or more sex hormones (Rosenthal and Peterson, 1996a), practitioners should be aware that serum cortisol is rarely elevated (if ever) and diagnostic testing for Cushing's disease based on cortisol levels will be of little or no diagnostic value.

The objective of the study was to determine whether a slow-release implant of the GnRH analogue deslorelin, has any value in the therapy of hyperoestrogenism of adrenocortical origin (NHA). For realistic monitoring we needed reference val-

ues, so blood samples for E_2 determination were also taken from intact, healthy (untreated control) females.

MATERIAL AND METHODS

Animals and design

The study was conducted on domesticated ferrets (*Mustela putorius furo*) ($n = 17$; age: nine months to four years; body weight: 800–1 000 g) of mild to moderate body condition, from private veterinary practices in Budapest and Veszprem. Owners gave their permission for the veterinary manipulations (blood sampling and/or treatment) in each case.

Healthy ferrets ($n = 14$) were used as control animals. These females were hospitalized for ovariectomy, either 3–10 days after the beginning of heat ($n = 5$), or 9–21 days after hCG induced ovulation ($n = 6$), or out of breeding season (in winter when ferrets were in anoestrus ($n = 3$)). The stage of ovarian function was confirmed by morphological examination of ovaries removed. Blood samples were taken at the beginning of the operative manipulation, after 6–8 hour long food deprivation, using intramuscular combination of ketamine (2.5 mg/100 g body weight; SBH-Ketamine inj., Produlab Pharma BV, Raamsdonksveer, The Netherlands) and xylazine (0.2 mg/100 g body weight; Rompun inj., Bayer AG, Leverkusen, Germany) for immobilization and anesthesia.

The case history of each neutered ferret ($n = 3$), showing pathognostic signs of endocrine alopecia, is detailed below. Each ferret had been showing clinical signs for three (*Emmy*) to eight weeks (*Pipi* and *Peti*) when blood samples were taken to determine E_2 concentrations. At that time, they were subcutaneously treated with 4.7 mg deslorelin acetate (Deslorelin implant[®], Peptech Animal Health, North Ryde, Australia). Blood samples for E_2 determination were again collected one month after the insertion of the implant.

The first ferret (*Emmy*) was a four year old female. She was neutered at the age of one year. After the ovariohysterectomy, she lost the hair on her tail periodically every year and had a swollen vulva every spring. Oestrous signs and hair loss resolved spontaneously every year, but at four years old, the hair loss remained persistent. First, her hair thinned at the base of the tail, inside the legs and around the genitals, than gradually it was lost over most

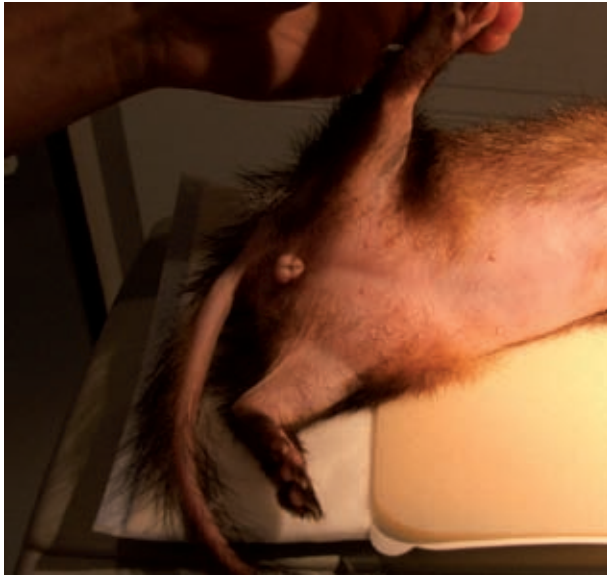

Figure 1. Female ferret (*Emmy*) showing swollen vulva and clinical sign of hyperoestrogenism (alopecia) after her ovariectomy

of the body (Figure 1). Body condition was very bad despite her good appetite. Later, she lost her appetite and became apathetic. As a first step, she was treated with 150 IU hCG (human chorionic gonadotropin) three times, seven days apart to exclude ORS. Despite this hormonal treatment, oestrous signs did not disappear and the clinical signs did not change. The second ferret (*Pipi*) was a three year old female. She was neutered during her pregnancy when she was two years old. Next spring after the ovariectomy she had developed a swollen vulva and began losing the hair on her tail and then on the dorsal side of her neck. This hair loss was

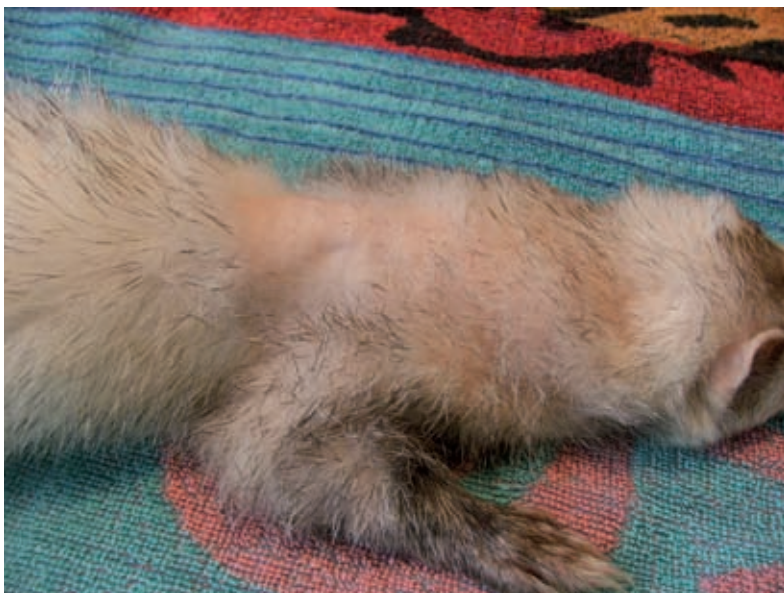

Figure 2. Male ferret (*Peti*) displaying endocrine alopecia due to hyperoestrogenism on the dorsal side of the neck three years after castration

dramatic. She had pruritus, her body condition was very bad, and she had no appetite. At first, it was suggested that she had ORS. Exploratory laparoscopy was done, but no hormone producing ovarian remnant could be seen in the abdominal cavity. A suitable volume of blood for E_2 determination could not be collected due to her bad body condition. The third ferret (*Peti*) was a four year old male. Three years after castration, typical endocrine alopecia was observed on the dorsal side of the neck, on the tail and on the fingers (Figure 2). His appetite and body condition were quite good. No weight loss was detected. Neither ectoparasite nor fungal infections were found. According to the case history and clinical signs, the suggested diagnosis was NHA in each ferret with hormonal alopecia.

Handling of blood samples. Laboratory and statistical procedures

Blood samples (2 ml) from each ferret were taken from the jugular vein into heparinized tubes. Samples were cooled and centrifuged within three hours. Plasma was harvested immediately, and stored at -20°C until E_2 measurements. E_2 in 0.5 ml of plasma were extracted with 5 ml of diethyl-ether (Reanal, Budapest, Hungary). After evaporation and resolving in assay buffer the E_2 content was determined by a commercial ^{125}I -RIA kit (3rd Generation Estradiol RIA, DSL-39100, Diagnostic Systems Laboratories, Inc., Webster, Texas, USA). However, before assaying the current samples, the analytical procedure was validated for ferret plasma: the

binding pattern of two serially diluted sample pools was parallel to that of the standard curves, and the recovery rates of added known quantity of E_2 were between 86 and 101% (added before extraction), and between 96 and 104% (added into the extract). The sensitivity and intra- and interassay CV of procedures were within the acceptable range (2.2 pmol/l, < 7.5% and < 16.4%).

For the presentation of results the group means and their standard errors (SEM) were expressed. The results were subjected to Student's *t*-test (for comparison of group means between healthy control females in oestrous and sick ferrets before deslorelin treatment, and between healthy control females in anoestrous/luteal phase and sick ferrets after deslorelin treatment and between sick ferrets before and after deslorelin treatment), or a single trait analysis of variance (ANOVA; for comparison of three group means in healthy control females). If ANOVA revealed significant differences, the least significant differences were planned to be calculated at 5% ($LSD_{p < 0.05}$) for further comparison. Bonferroni's *t*-test was used in all pairwise multiple comparison procedures.

RESULTS

The morphological examination of ovaries from healthy ferrets showed the expected physiological characteristics. Ovaries of females in heat ($n = 5$)

contained 3–9 tertiary follicles, whilst those of ferrets treated with hCG had 2–10 well developed corpora lutea. Animals, spayed in anoestrus, did not have any follicle or *corpus luteum*-like tissue on their ovaries. Control females in oestrous had higher E_2 concentrations than control females in anoestrous and in the luteal phase ($P \leq 0.001$).

Before deslorelin acetate treatment, two ferrets with suspected NHA showed high E_2 concentrations in plasma. These values (*Emmy*: 139.9 pmol/l and *Peti*: 99.45 pmol/l) were similar to healthy, untreated, control female E_2 concentrations in estrus (61.6–123.02 pmol/l, $n = 5$) ($P = 0.229$) (Figure 3). In the third, unsuccessfully bled female (*Pipi*), hyperoestrogenism was supposed due to a swollen vulva together with clinical signs (alopecia).

Some weeks after the deslorelin implant insertion, all previously alopecic ferrets ($n = 3$) had recovered. Hair growth had resumed, good appetite had returned, and body condition was improving in each case. In the females, vulval swelling had disappeared. In plasma samples of the two bled ferrets, E_2 concentrations significantly decreased compared to the pre-treatment values ($P = 0.035$). E_2 concentrations reached the baseline values (*Emmy*: 12.89 pmol/l and *Peti*: 16.08 pmol/l) typical to females in luteal phase and in anoestrous (12.0–30.58 pmol/l, $n = 9$) ($P = 0.137$) (Figure 3). All treated ferrets were re-examined 19–21 months after deslorelin implant insertion and all of them had normal fur and were clinically healthy.

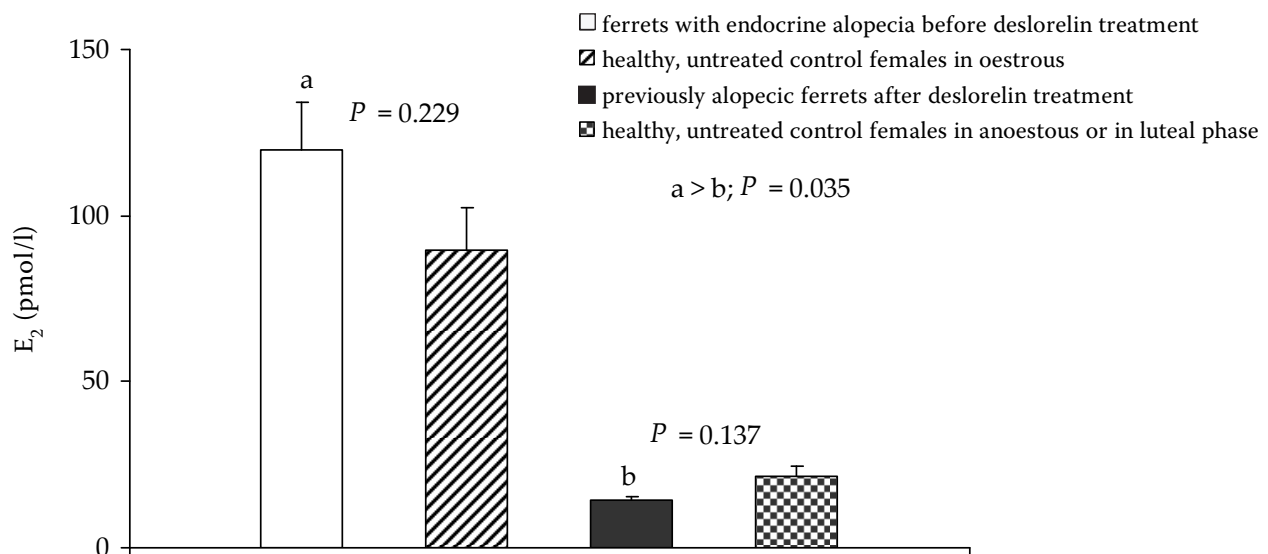


Figure 3. Estradiol concentrations in healthy control female ferrets in oestrous ($n = 5$), and in anoestrous ($n = 6$) or luteal phase ($n = 3$), and in deslorelin acetate treated ferrets with NHA signs ($n = 3$) (just before and one month after implant insertion) (mean \pm SEM)

DISCUSSION

In this small, practice-oriented study, 14 healthy, untreated control females at different stages of the ovarian cycle and three neutered ferrets ($n = 2$ females and $n = 1$ male) with suggested hyperadrenocorticism were included. All three neutered ferrets showed clinical signs of hormonal disorder (typical alopecia and swollen vulva in females). One female (*Emmy*) had periodically occurring alopecia for four years before her hair loss became permanent. The possible explanation of this phenomenon is that alopecia and other clinical signs of adrenocortical diseases may remit during autumn and winter in response to the decline in LH associated with the shortening photoperiod (Fox and Marini, 1998). However, at an advanced stage, the seasonal disappearance of the clinical signs stops and they become permanent (Rosenthal et al., 1993).

In our study, based on the clinical signs (oestrous in females and hormonal alopecia in both genders), plasma E_2 concentrations were measured. ORS in the females was excluded based on the unsuccessful hCG treatments for induction of ovulation and exploratory laparoscopy for detecting retained ovarian tissue. The diagnosis therefore was NHA in each female. In the castrated male, after excluding ectoparasite or fungal infections, the diagnosis was also NHA. In ferrets, adrenal-associated endocrinopathy is different from Cushing's disease in other species. Instead of an elevated cortisol concentration, an increased secretion of sex hormone(s) due to elevated LH concentrations following gonadectomy can be seen in ferrets. Rosenthal and Peterson (1996a) showed that no one specific sex hormone was elevated in all ferrets. High concentrations of androstenedione, 17-hydroxyprogesterone, and estradiol could be detected most frequently and at least one of these three hormones was detected in all ferrets. In our study, elevated plasma E_2 concentrations similar to the healthy control females in oestrous were measured in each sampled ferrets with hormonal alopecia. The assay for E_2 determination was validated for ferrets in the author's laboratory and the normal range of E_2 in 14 healthy (untreated control) ferrets was established.

Recently, two treatment modalities have been used to cure this disease: surgical removal of the affected gland(s) or medical treatment. In the last 10 years, adrenalectomy has been the preferred treatment for ferrets (Lawrence et al., 1993; Rosenthal et al.,

1993; Wagner and Dorn, 1994; Weiss and Scott, 1997). Whilst the prognosis with this method can be good, in cases of unilateral adrenalectomy complications may occur due to the possible development of adrenal disease in the remaining adrenal gland. In recent years, medical management of the disease has come to the fore. However, some drugs (mitotane and ketokonazole) generally used in the therapy of Cushing's disease in other species prove ineffective for ferrets' NHA (Rosenthal, 1997) and other drugs (androgen receptor blockers, aromatase inhibitors) are effective only in some, but not all ferrets (Quesenberry and Rosenthal, 2004). Drugs controlling reproductive functions are promising treatment options. One of them, melatonin (5.4 mg melatonin implant, Prime-X registered for mink), has been administered with success to ferrets ($n = 100$) with NHA by Murray (personal communication). The supposed length of its efficacy was 3–4 months. Ramer et al. (2006) studied the oral administration of melatonin. Their results showed that it decreased clinical signs associated with adrenocortical disease in ferrets, but that daily treatment over the course of months did not decrease adrenal gland tumor growth. The GnRH agonists may be other therapeutic possibilities bearing in mind the background of the pathomechanism of this disease. GnRH agonists used as long-term therapy down-regulate GnRH receptors of gonadotrophs of the pituitary gland and inhibit elevated LH secretion. An injectable GnRH agonist, leuprolide acetate, was used in ferrets ($n = 20$) in a single dose of 100 μg per animal by Wagner et al. (2001). They showed that this treatment reduced the elevated estradiol, 17 α -hydroxyprogesterone, androstenedione, and dehydroepiandrosterone concentrations and eliminated the clinical signs of NHA (vulvar swelling, pruritus, alopecia and undesirable sexual behaviors and aggression). The treatment effects were temporary and typically after three months, clinical signs reoccurred in all ferrets. More recently another drug, deslorelin acetate, was used as a long-lasting treatment. deslorelin acetate is used more and more commonly in the reproductive management and veterinary praxis. It was found that deslorelin acetate reversibly suppressed reproductive function in several species (e.g. male and female dogs, female eastern grey kangaroos, female cats and ferrets) for extended periods (Munson et al., 2001; Prohaczik et al., 2003; Gobello, 2006; Herbert et al., 2006; Schoemaker et al., 2008). Moreover, seeing that such treatment

caused long-term reduction of circulating FSH and LH concentrations to very low or undetectable levels, it was successfully used in the treatment of urinary incontinence in neutered female dogs (Reichler et al., 2003). References of studies using deslorelin treatment are also available in farm animals for ovulation induction, ovarian function suppression etc. (Kraeling et al., 2000; Silvestre et al., 2009). Delbecchi and Lacasse (2006) found that such treatment could temporarily suppress the return of ovarian cycles in cows. This study described that deslorelin significantly reduced serum concentrations of 17 beta-estradiol and progesterone as compared with untreated cows.

Wagner et al. (2005) reported a study in which 15 ferrets with NHA were subcutaneously treated with a single 3-mg implant of deslorelin acetate. Compared with findings before treatment, vulvar swelling and pruritus were reduced or eliminated completely within two weeks after implant insertion. Four to six weeks post-insertion, fur had re-grown. One month post-treatment, estradiol, androstenedione, and 17-hydroxyprogesterone concentrations decreased and remained low until clinical recidivism. The average time to reoccurrence of clinical signs was 13.7 ± 3.5 months (range, 8.5–20.5 months).

Based on our results, which show the safety and efficacy of using deslorelin acetate (4.7 mg) to suppress ovarian function in intact female ferrets for ≥ 1.5 years (Prohaczik et al., 2003), the three ferrets with clinical signs of NHA included in this study were subcutaneously treated with a deslorelin implant (4.7 mg per animal, irrespective of body weight). Our results indicate that such treatment was able to alleviate clinical signs and elevated E_2 concentrations in the affected animals for a long period (> 19 months).

In summary, decreasing E_2 levels and improving clinical signs after deslorelin treatment prove that E_2 was the cause of hair loss in neutered ferrets with hormonal alopecia. E_2 was probably produced by the adrenal gland. The secretion of sex steroids in ferrets (particularly E_2 production) was efficiently suppressed by 4.7 mg deslorelin acetate for > 19 months.

REFERENCES

- Bielinska M., Kiiveri S., Parviainen H., Mannisto S., Heikinheimo M., Wilson D.B. (2006): Gonadectomy-induced adrenocortical neoplasia in the domestic ferret (*Mustela putorius furo*) and laboratory mouse. *Veterinary Pathology*, 43, 97–117.
- Coleman G.D., Chavez M.A., Williams B.H. (1998): Cystic prostatic disease associated with adrenocortical lesions in the ferret (*Mustela putorius furo*). *Veterinary Pathology*, 35, 547–549.
- Delbecchi L., Lacasse P. (2006): Short communication: Suppression of estrous cycles in lactating cows has no effect on milk production. *Journal of Dairy Science*, 89, 636–639.
- DeNardo G.A., Becker K., Brown N.O., Dobbins S. (2001): Ovarian remnant syndrome: revascularization of free-floating ovarian tissue in the feline abdominal cavity. *Journal of the American Animal Hospital Association*, 37, 290–296.
- Fox J.G., Marini R.P. (1998): Disease of the endocrine system. In: Fox J.G. (ed.): *Biology and Diseases of the Ferret*. 2nd ed. Williams and Wilkins Press, London. 294 pp.
- Gobello C. (2006): Dopamine agonists, anti-progestins, anti-androgens, long-term-release GnRH agonists and anti-estrogens in canine reproduction: A review. *Theriogenology*, 66, 1560–1567.
- Herbert C.A., Trigg T.E., Cooper D.W. (2006): Fertility control in female eastern grey kangaroos using the GnRH agonist deslorelin. 1. Effects on reproduction. *Wildlife Research*, 33, 41–46.
- Hillyer E. (1992): Ferret Endocrinology. In: Kirk R.W., Bonagura J.D. (eds.): *Current Veterinary Therapy XI: Small Animal Practice*. WB Saunders, Philadelphia. 1185 pp.
- Kraeling R.R., Barb C.R., Rampacek G.B., Thompson D.L., Gibson J.W., Sullivan S.A., Simon B., Burns P.J. (2000): Luteinizing hormone response to controlled-release deslorelin in estradiol benzoate primed ovariectomized gilts. *Theriogenology*, 53, 1681–1689.
- Lawrence H.J., Gould W.J., Flanders J.A., Rowland P.H., Yeager A.E. (1993): Unilateral adrenalectomy as a treatment for adrenocortical tumors in ferrets: five cases (1990–1992). *Journal of the American Veterinary Medical Association*, 203, 267–270.
- Lipman N.S., Marini R.P., Murphy J.C., Zhibi Z., Fox J.G. (1993): Estradiol-17 beta-secreting adrenocortical tumor in a ferret. *Journal of the American Veterinary Medical Association*, 203, 1552–1555.
- Munson L., Bauman J.E., Asa C.S., Jochle W., Trigg T.E. (2001): Efficacy of the GnRH analogue deslorelin for suppression of oestrous cycles in cats. *Journal of Reproduction and Fertility*, 57(Suppl.), 269–273.
- Patterson M.M., Rogers A.B., Schrenzel M.D., Marini R.P., Fox J.G. (2003): Alopecia attributed to neoplastic

- ovarian tissue in two ferrets. *Comparative Medicine*, 53, 213–217.
- Prohaczik A., Kulcsar M., Trigg T., Huszenicza Gy. (2003): Treatments suppressing ovarian activity in ferret (*Mustela putorius furo*). *Reproduction in Domestic Animals*, 38, 331.
- Quesenberry K.E., Rosenthal K.L. (2004): Endocrine disease. In: Quesenberry K.E., Carpenter J.W. (eds.): *Ferrets, Rabbits and Rodents Clinical Medicine and Surgery*. W.B. Saunders Press, United States of America. 86–87.
- Ramer J.C., Benson K.G., Morrisey J.K., O'Brien R.T., Paul-Murphy J. (2006): Effects of melatonin administration on the clinical course of adrenocortical disease in domestic ferrets. *Journal of the American Veterinary Medical Association*, 229, 1743–1748.
- Reichler I.M., Hubler M., Jochle W., Trigg T.E., Piche C.A., Arnold S. (2003): The effect of GnRH analogs on urinary incontinence after ablation of the ovaries in dogs. *Theriogenology*, 60, 1207–1216.
- Rosenthal K.L. (1997): Adrenal gland disease in ferrets. *The veterinary clinics of North America. Small Animal Practice*, 27, 401–418.
- Rosenthal K.L., Peterson M.E. (1996a): Evaluation of plasma androgen and estrogen concentration in ferrets with hyperadrenocorticism. *Journal of the American Veterinary Medical Association*, 209, 1097–1102.
- Rosenthal K.L., Peterson M.E. (1996b): Stranguria in a castrated male ferret. *Journal of the American Veterinary Medical Association*, 209, 62–63.
- Rosenthal K.L., Peterson M.E., Quesenberry K.E., Hillyer E.V., Beeber N.L., Moroff S.D., Lothrop C.D.Jr. (1993): Hyperadrenocorticism associated with adrenocortical tumor or nodular hyperplasia of the adrenal gland in ferrets: 50 cases (1987–1991). *Journal of the American Veterinary Medical Association*, 203, 271–275.
- Schoemaker N.J. (2003): Hyperadrenocorticism in ferrets. [PhD dissertation.] Faculty of Veterinary Medicine, Utrecht.
- Schoemaker N.J., Schuurmans M., Moorman H., Lumeij J.T. (2000): Correlation between age at neutering and age at onset of hyperadrenocorticism in ferrets. *Journal of the American Veterinary Medical Association*, 216, 195–197.
- Schoemaker N.J., Teerds K.J., Mol J.A., Lumeij J.T., Thijssen J.H., Rijnberk A. (2002): The role of luteinizing hormone in the pathogenesis of hyperadrenocorticism in neutered ferrets. *Molecular and Cellular Endocrinology*, 197, 117–125.
- Schoemaker N.J., van der Hage M.H., Flik G., Lumeij J.T., Rijnberk A. (2004): Morphology of the pituitary gland in ferrets (*Mustela putorius furo*) with hyperadrenocorticism. *Journal of comparative pathology*, 130, 255–265.
- Schoemaker N.J., van Deijk R., Muijlaert B., Kik M.J., Kuijten A.M., de Jong F.H., Trigg T.E., Kruitwagen C.L., Mol J.A. (2008): Use of a gonadotropin releasing hormone agonist implant as an alternative for surgical castration in male ferrets (*Mustela putorius furo*). *Theriogenology*, 70, 161–167.
- Silvestre F.T., Bartolome J.A., Kamimura S., Arteché A.C., Pancarci S.M., Trigg T., Thatcher W.W. (2009): Postpartum suppression of ovarian activity with a Deslorelin implant enhanced uterine involution in lactating dairy cows. *Animal Reproduction Science*, 110, 79–95.
- Wagner R.A., Dorn D.P. (1994): Evaluation of serum estradiol concentrations in alopecic ferrets with adrenal gland tumors. *Journal of the American Veterinary Medical Association*, 205, 703–707.
- Wagner R.A., Bailey E.M., Schneider J.F., Oliver J.W. (2001): Leuprolide acetate treatment of adrenocortical disease in ferrets. *Journal of the American Veterinary Medical Association*, 218, 1272–1274.
- Wagner R.A., Piche C.A., Jochle W., Oliver J.W. (2005): Clinical and endocrine responses to treatment with deslorelin acetate implants in ferrets with adrenocortical disease. *American journal of veterinary research*, 66, 910–914.
- Weiss C.A., Scott M.V. (1997): Clinical aspects and surgical treatment of hyperadrenocorticism in the domestic ferret: 94 cases (1994–1996). *Journal of the American Animal Hospital Association*, 33, 487–493.
- Weiss C.A., Williams B.H., Scott J.B., Scott M.V. (1999): Surgical treatment and long-term outcome of ferrets with bilateral adrenal tumors or adrenal hyperplasia: 56 cases (1994–1997). *Journal of the American Veterinary Medical Association*, 215, 820–823.
- Whaler C.L., Kamieniecki C.L. (1998): Ferret adrenal-associated endocrinopathy. *The Canadian Veterinary Journal*, 39, 175–176.

Received: 2009–02–15

Accepted after corrections: 2009–02–28

Corresponding Author:

Gyula Huszenicza, Szent Istvan University, Faculty of Veterinary Science, Istvan u. 2, H-1078 Budapest, Hungary
Tel. +36 1 478 4202, E-mail: huszenicza.gyula@aotk.szie.hu