

Co-infection with papillomavirus and *Knemidokoptes jamaicensis* (Acari: Knemidokoptidae) in a chaffinch (*Fringilla coelebs*) and a case of beak papillomatosis in another chaffinch

I. LITERAK¹, B. SMID², F. DUSBABEK³, R. HALOUZKA⁴, L. NOVOTNY⁴

¹Department of Biology and Wildlife Diseases, Faculty of Veterinary Hygiene and Ecology,

⁴Department of Pathological Morphology, Faculty of Veterinary Medicine, University of Veterinary and Pharmaceutical Sciences, Brno, Czech Republic

²Veterinary Research Institute, Brno, Czech Republic

³Institute of Parasitology, Academy of Sciences of the Czech Republic, Ceske Budejovice, Czech Republic

ABSTRACT: Nodular papillomatous lesions combined with proliferation and formation of scales and crusts were observed on both tarsi of a dead chaffinch (*Fringilla coelebs*) found in February 2004 in the eastern part of the Czech Republic. Electron microscopic examination demonstrated the presence of papillomavirus virions in the lesions. The parasitological examination of crust scraps revealed the presence of mites *Knemidokoptes jamaicensis*. Skin lesions were caused by a co-infection with the two pathogens. This paper is the first report of such a co-infection. In another chaffinch netted in May 2004 in the northern part of the Czech Republic, marked papillomatous lesions were found at the base of the beak. Proliferation of basal epidermal cells with sporadic intranuclear inclusions in the keratinocytes of *stratum granulosum* of the epidermis observed in the histopathological examination was suggestive of a viral aetiology of the papillomatous lesions. This is the first reported case of beak papillomatosis in the chaffinch.

Keywords: bird; Czech Republic; disease; mite; parasite; virus

Papillomatosis is rare in wild birds. The most frequent incidence of the disease is among the chaffinch (*Fringilla coelebs*) (Literak et al., 2003). Chaffinches with papillomatosis have been reported from the United Kingdom, Germany, The Netherlands, Sweden and the Czech Republic (see a review in Literak et al., 2003; Rajchard and Rachac, 2003). In all the cases reported to date, papillomatous lesions were localized on the legs of the birds where they affected digits and the tarsus. The

papilloma showed stages of development from a slight node on a digit to a heavy involvement of the foot and the tarsometatarsus; in severe cases, the tumour might account for 5% of the body weight (Lina et al., 1973).

Papillomatous lesions on other parts of the chaffinch body have never been reported before (Literak et al., 2003). The virus causing papillomatous lesions on chaffinch legs has been classified as belonging to the genus *Papillomavirus* and named

Partially supported by the Ministry of Education, Youth and Sports of the Czech Republic (Grant No. MSM 6215712402). Support for B.S. was provided by Ministry of Agriculture of the Czech Republic (Grant No. 0002716201); F.D. was supported by the Institutional Research Project No. Z 60220518 from the Institute of Parasitology, Ceske Budejovice, Czech Republic.

FPV (Fringilla Papillomavirus) (Osterhaus et al., 1977; Moreno-Lopez et al., 1984). Papillomatous lesions have been found on the legs of some other bird species, namely captive water birds (Zangger and Muller, 1990) and greenfinches (*Carduelis chloris*) (Sironi and Gallazzi, 1992).

Papillomatous growths on chaffinch legs are characteristically shaped and their diagnosis is based on the evaluation of the growth morphology by histopathological or electron microscopic examinations (Literak et al., 2003). Tarsi and digits of chaffinches and other species of wild birds may also be afflicted with compact nodular growths caused by avipoxvirus (Bolte et al., 1999), and with burrowing mites of the genus *Knemidokoptes* of the family Knemidokoptidae that cause scaly leg disease with wart-like skin proliferations. *Knemidokoptes jamaicensis* (Turk, 1950) causing scaly leg disease has been found in chaffinches (MacDonald, 1962). The authors are not aware of any report of co-infections affecting feet of chaffinches.

The aim of the present study was to describe a co-infection involving papillomatosis and mites *K. jamaicensis* in one chaffinch, and papillomatous growths on the head of another chaffinch.

Case report 1

Birds fed at a feeder in a forest near the village of Zahlinice (49.17 N, 17.30 E) in the eastern part of the Czech Republic were ornithologically examined by J. Sitko in winter 2003/2004. The feeder was regularly visited by a flock of about 20 chaffinches. On 14 February 2004, a dead chaffinch with lesions on both its legs was found at the feeder. The carcass was subsequently frozen at -18°C and taken to the laboratory for further examination.

There was a swelling on both tarsi and the base of the digits. Tumorous lesions of the papillomatous character were combined with formation of crusts. Samples were collected from both legs for histopathological, electron microscopic and parasitological examinations.

Histopathological examination. The freezing of the carcass and subsequent postmortem changes precluded detailed histopathological examination.

Electron microscopic examination. Tissue samples collected from the skin lesion were prepared for electron microscopy by the negative staining technique. Small pieces of tissue (approximately

0.5 mm^3) were lysed in several drops of distilled water and a grid coated with a formvar film and carbon was put onto the surface of the lysate. After 15 s, the grid was removed and residual water was sucked off from its surface with a strip of filter paper. The preparation was treated with one drop of 2% water solution of ammonium molybdate for several seconds and, after sucking the excess stain off, it was ready for viewing in the electron microscope Philips EM 208 (Philips, The Netherlands). The examination demonstrated typical papillomavirus virions composed of capsomeres arranged in icosahedral symmetry of the capsid. The diameter of the virions was approximately 52 to 55 nm (Figure 1).

For parasitological investigation, scraps of leg crusts were examined in 70% alcohol under stereomicroscope (Technival, Carl Zeiss, Jena, Germany). The mites collected were mounted in Hoyer's medium on glass slides and examined under microscope (Amplival, Carl Zeiss). The mites found were determined according to the revision of mites of the genus *Knemidokoptes* by Fain and Elsen (1967) as *K. jamaicensis* (Figure 2). Two slides with numerous females and larvae have been deposited in the collection of the Institute of Parasitology,

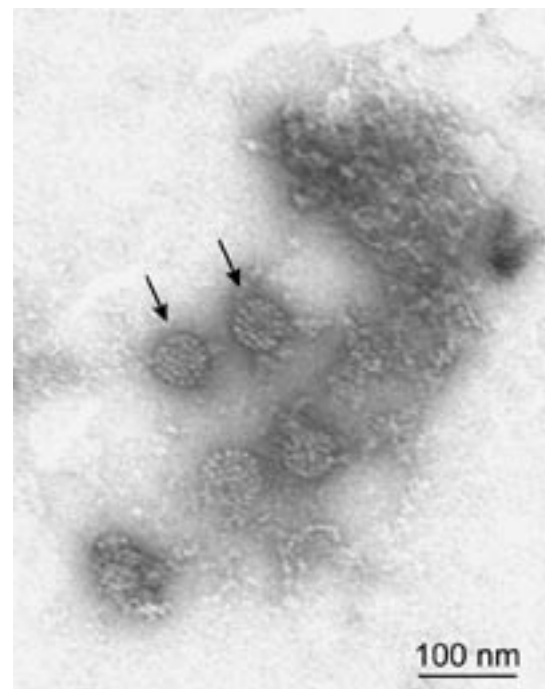


Figure 1. The papilloma virions (arrows). Negative staining with 2% water solution of ammonium molybdate, pH 7. Photo: B. Smid

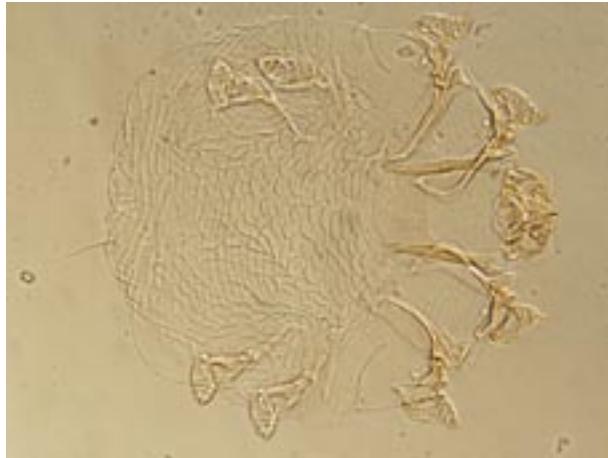


Figure 2. *Knemidokoptes jamaicensis* (Turk, 1950) female; length 320 µm. Photo: F. Dusbabek

Academy of Sciences of the Czech Republic in Ceske Budejovice under numbers PaU AV CR 2000 and PaU AV CR 2001.

The cause of lesions on the legs of the chaffinch was a co-infection with papilloma virus and mites *K. jamaicensis*.

Case report 2

On 30 May 2004, wild birds were netted and ringed by M. Hromadko in Orlicke Zahori (50.17 N, 16.28 E) in the north of the Czech Republic. One of the six chaffinches netted there had a major lesion on the beak (Figure 3). Extensive papillomatous lesions located in the midline and on the right side of the base of the beak affected mainly the upper



Figure 3. Papillomatous growths on the beak of a chaffinch. Photo: I. Literak

jaw, although smaller lesions were also found on the base of lower jaw. Papillomatous growths even proliferated into the beak cavity. Some of the easily detachable papillomas were removed and stored in 70% ethanol for subsequent histopathological examination. When the samples were collected, the chaffinch was again released.

Histopathological examination. The specimens were processed by a standard paraffin technique and stained with haematoxylin-eosin. Sections of 5 µm in thickness were examined under an optical microscope Olympus BX-51 (Olympus, Japan). The examination revealed hypertrophy of keratinocytes, excessive hyperkeratosis of the *stratum corneum* of the epidermis with acanthosis and formation into papillomatous projections (Figure 4). Proliferation of basal epidermal cells with sporadic intranuclear inclusions in the *stratum granulosum* of the epidermis was suggestive of viral aetiology of the papillomatous growths.

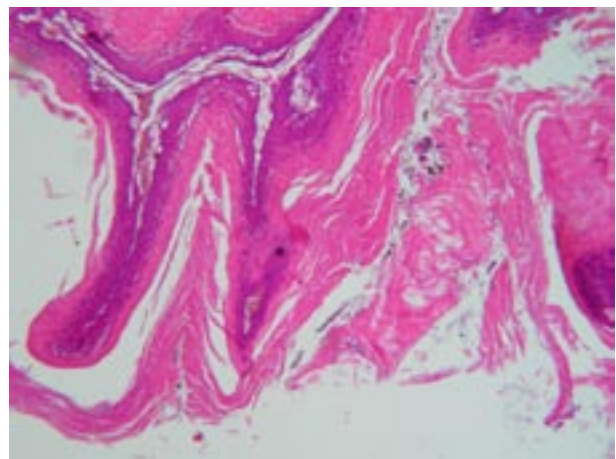


Figure 4. Histological section of the epidermis of a chaffinch shows hyperkeratosis, papillomatous projections of affected epidermis, acanthosis and abundant keratinous masses between papillomatous projections. HE, 400×. Photo: L. Novotny

DISCUSSION

Papillomaviruses are strictly host-specific DNA viruses that induce development of mostly benign, but occasionally malignant, neoplastic lesions in mammals and birds. Compared with mammalian infections, reports on avian papillomatosis are rather scarce (Sironi and Gallazzi, 1992). Papillomatosis in chaffinches is an exception, and its incidence in western, northern and central Europe is relatively

frequent (Literak et al., 2003). Investigation into the effect of papillomatosis on health of infected chaffinches or on the health of the chaffinch population in the focus of the infection has not been made to date.

K. jamaicensis was originally described from golden thrush (*Turdus aurantiacus*) in Jamaica. Subsequently, it has been collected from more than 30 passerine bird species predominantly in North America, but also in Europe, South Africa and Sri Lanka (Fain and Elsen, 1967). European collections originate from England, Denmark and Austria from birds of the families Fringillidae (9 species) and Alaudidae (1 species). On chaffinch, the mite was collected in England and Denmark (MacDonald, 1962; Poulsen, 1964). There are no data on the prevalence of *K. jamaicensis* on birds in Europe. However, prevalences of infestation in the Dominican Republic in passerines were 18 to 25 % (Latta and O'Connor, 2001; Latta, 2003). In Oklahoma, USA, Pence et al. (1999) estimated that 60–80% of American robin (*Turdus migratorius*) had lesions consistent with knemidokoptic mange. Latta (2003) observed that parasitized palm warblers (*Dendroica palmarum*) showed significant decrease in mean pectoral muscle mass scores indicating negative effect on body condition and physiological stress. He concluded that infestation had a significant effect on overwinter site persistence and annual return rates; no infected individuals ever returned the following year.

A co-infection with papillomavirus and *K. jamaicensis* mites has never been reported before. Although each of the infections alone may affect health of the bird, a co-infection will certainly prove much more of a burden and it may even be the cause of death, particularly under harsh winter conditions. We assume that it is what happened in this case. We may hypothesize that one of the infections predisposes to the other. It was easier for the second pathogen to infect the tissue damaged by the first one. It is difficult to say, however, which was the primary infection.

It was not immediately clear from a cursory inspection of the lesions on the chaffinch's legs that it was a case of co-infection with two pathogens. If only virological or only pathological examination had been made, the result would have been incomplete. We should consider the possibility that results of some of the hitherto published examinations of leg lesions in chaffinches (and some other birds) may be incomplete for this reason. This is

particularly true about past works relying exclusively on visual characterisation of lesions (see review in Literak et al., 2003). In future examinations of similar lesions in wild birds, it would be very useful to pay attention to both pathogens found in the present study as well as to the avipoxvirus aetiology of nodular changes on the extremities of the birds.

In chaffinches, papillomatous growths are characteristically located on the featherless parts of their legs (Literak et al., 2003), and their localization on the beak and inside the beak cavity is unusual. Avipoxvirus lesions on the beak, however, are found relatively frequently (Bolte et al. 1999, Literak et al., 2001). There have, however, been several reports of papillomatous growths on the head of parrots: in one African grey parrot (*Psittacus erithacus*), papillomavirus was isolated from skin lesions on the head (O'Banion et al., 1992). The virus was named PePV and a comparison of its DNA with the DNA of FPV showed that the former was a unique parrot papillomavirus (O'Banion et al., 1992). It is possible that PePV is typically located on the head, while the characteristic site for FPV is on the legs. The question whether the virus that caused beak papillomatosis in the chaffinch was identical with the viruses that cause papillomatosis on the legs remains unanswered.

Papillomatous lesions on the beak are certain to handicap the bird affected, and, in view of the long-lasting character of the lesion, it may be a life-long handicap: papillomatous lesions in greenfinches in captivity lasted for the entire 15-month period of monitoring (Sironi and Gallazzi, 1992).

REFERENCES

- Bolte A.L., Meurer J., Kaleta E.F. (1999): Avian host spectrum of avipoxviruses. *Avian Pathology*, 28, 415–432.
- Fain A., Elsen P. (1967): Les acariens de la famille Knemidokoptidae producteurs de gale chez les oiseaux (Sarcoptiformes). *Acta Zoologica et Pathologica Antverpiensia*, 45, 3–145.
- Latta S.C. (2003): Effects of scaly-leg mite infestation on body condition and site fidelity of migratory warblers in Dominican Republic. *Auk*, 120, 730–743.
- Latta S.C., O'Connor B.M. (2001): Patterns of *Knemidokoptes jamaicensis* (Acari: Knemidokoptidae) infestations among eight new avian hosts in the Dominican Republic. *Journal of Medical Entomology*, 38, 437–440.

- Lina P.H.C., Noord M.J. van, Groot F.G. de (1973): Detection of virus in squamous papillomas of the wild bird species *Fringilla coelebs*. Journal of the National Cancer Institute, 50, 567–571.
- Literak I., Halouzka R., Hromadko M., Honza M., Pinowska B., Haman A. (2001): Avipoxvirus infection in wild birds: new findings from Slovakia and Poland. Acta Veterinaria Brno, 70, 339–344.
- Literak I., Smíd B., Valicek L. (2003): Papillomatosis in chaffinches (*Fringilla coelebs*) in the Czech Republic and Germany. Veterinarni Medicina, 48, 169–173.
- MacDonald J.W. (1962): Chaffinch with cnemidoptict mange. British Birds, 55, 421.
- Moreno-Lopez J., Ahola H., Stenlund A., Osterhaus A., Pettersson U. (1984): Genome of an avian papillomavirus. Journal of Virology, 51, 872–852.
- O'Banion M.K., Jacobson E.R., Sundberg J.P. (1992): Molecular cloning and partial characterization of a parrot papillomavirus. Intervirology, 33, 91–96.
- Osterhaus A.D.M.E., Ellens D.J., Horzinek M.C. (1977): Identification and characterization of a papillomavirus from birds (Fringillidae). Intervirology, 8, 351–359.
- Poulsen H. (1964): Scaly-leg in captive birds. Avicultural Magazine, 70, 69
- Pence D.B., Cole R.A., Bruger K.E., Fischer J.R. (1999): Epizootic podoknemidokoptiasis in American robins. Journal of Wildlife Diseases, 35, 1–7.
- Rajchard J., Rachac V. (2003): *Papilloma squamocellulare* in chaffinch (*Fringilla coelebs*). Veterinarni Medicina, 48, 235–236.
- Sironi G., Gallazzi D. (1992): Papillomavirus infection in greenfinches (*Carduelis chloris*). Journal of Veterinary Medicine B, 39, 454–458.
- Turk F.A. (1950): A new species of parasitic mite, *Cnemidocoptes jamaicensis*, a causative agent of scaly-leg in *Turdus aurantiacus*. Parasitology, 40, 60–62.
- Zangger N., Müller M. (1990): Endemic papillomatosis of viral origin in water fowl of the Zoological Garden Basle. Schweizer Archiv Tierheilkunde, 132, 483.

Received: 05–01–13

Accepted after corrections: 05–05–13

Corresponding Author

Prof. MVDr. Ivan Literak, CSc., Department of Biology and Wildlife Diseases, Faculty of Veterinary Hygiene and Ecology, University of Veterinary and Pharmaceutical Sciences, Palackeho 1–3, 612 42 Brno, Czech Republic
Tel. +420 541 562 630, fax +420 549 243 020, e-mail: literaki@vfu.cz
