

Treatment of canine hip dysplasia using triple pelvic osteotomy

K. ALTUNATMAZ, R. YUCEL, Y. DEVECIOGLU, M. SAROGLU, S. OZSOY

Surgery Department, Faculty of Veterinary Medicine, Istanbul University, Avcilar, Istanbul, Turkey

ABSTRACT: In this study, triple pelvic osteotomy (TPO) was carried out in a total of 22 dysplastic dogs, of which 9 were treated bilaterally and 13 unilaterally, and the position of the acetabulum was changed in a total of 31 hip joints using a special plate. It was established that, of the treated hip joints, 16 had severe, 12 medium and 3 mild dysplasia, the Norberg angle was between 70–92° and that the covering rate of the acetabulum over the femoral head changed between 5–42°. In the radiographs taken immediately after the operation, the covering rate of the acetabulum over the femoral head was determined to be very good in 25 hip joints (75% and over) and good in 6 joints (60–75%). In 5 cases, some of the screws holding the plate in place were seen to loosen in radiographs. However, this did not have any effect on the angle given to the acetabulum. In radiographs obtained 6–48 months later, degenerative joint disease was not encountered in 29 cases, with the exception of 2 cases. It was concluded that hip dysplasia, which is a hereditary disease, can be treated reasonably successfully in young dogs with TPO carried out before degenerative changes begin to occur in the joint.

Keywords: hip dysplasia; triple pelvic osteotomy; dog

Hip dysplasia is a condition characterized by impaired development of the hip joint, which affects the puppies of large and giant breed dogs (Alexander, 1992; Lust, 1993; Plante *et al.*, 1997; Piermatei and Flo, 1997). The dogs are born with normal hip joints. During growth, however, there may be incoordination between the skeleton and the supporting muscular system (Alexander, 1992). Abnormal forces created by joint incongruency cause degenerative joint disease (Lust, 1997; Plante *et al.*, 1997).

While genetic factors play the most significant role in the formation of hip dysplasia, other causes of hip dysplasia include; body type and development, feeding, uncoordinated development of muscle and bone, hormones and trauma/exercise (Smith *et al.*, 1990; Alexander, 1992; Wallace and Olmstead, 1995; Cardinet *et al.*, 1997; Piermatei and Flo, 1997; Plante *et al.*, 1997). While hip dysplasia is generally observed in dogs aged between 4–12 months and predisposed to the disease, radiological appearance of degenerative changes may be as late as 24 months (Corley, 1992; Lust, 1997). The first symptom of dysplasia is laxity in the hip joint. While it is possible for the presence of laxity to be detected

radiographically at 2–4 months of age (Smith *et al.*, 1990, 1998), the most reliable period is at 8 months (Lust, 1997). In the later stages of the disease, clinical symptoms such as a swinging gait and easy tiring are seen (Piermatei and Flo, 1997; Denny and Butterworth, 2000).

Clinical and radiological examination is used in the diagnosis of hip dysplasia. In symmetrical ventro-dorsal (VD) radiographs, joints with a Norberg angle of over 105° and those with more than 50% of the femoral head inside the acetabulum are considered to be normal (Smith, 1997). However, it has been reported that these values cannot be definite proof in every dog breed and that in a perfect hip joint there has to be a “C-shaped” acetabulum covering 75% or more of the femoral head (Henry, 1992; Tomlinson and Johnson, 2000). This is why measurements done in stress radiographs (distraction index) have been reported to give more reliable results (Smith *et al.*, 1990, 1998),

Classification of hip dysplasia has been made by the Orthopedic Foundation for Animals (OFA) as follows: excellent hip joint conformation, good hip joint conformation, fair hip joint conformation,

mild dysplastic hip joint, moderate dysplastic hip joint and severely dysplastic hip joint (Henry, 1992; Plante *et al.*, 1997).

Methods used in the treatment of hip dysplasia include conservative (medical, acupuncture, dietary changes, confining to restricted cages etc.) and operative (total hip replacement, triple pelvic osteotomy, excision arthroplasty, darthroplasty etc.) according to the animal's age, weight, clinical symptoms and the financial position of the patient owner (Slocum and Slocum, 1992; Plante *et al.*, 1997).

The purpose of treating dysplastic dogs using triple pelvic osteotomy (TPO) is to improve the function of the leg and minimize the possible occurrence of degenerative joint disease (Slocum and Slocum, 1992; Plante *et al.*, 1997). In doing this, it is aimed to provide a normal movement area by totally covering the femoral head and by increasing the contact surface between the joints, decreasing the pressure exerted on each point and so providing the most stability (Wallace and Olmstead, 1995; Dejardin *et al.*, 1998).

MATERIAL AND METHOD

The material of the study comprised of 22 dogs of different breed, age, gender and body weight. The dogs to undergo TPO were first given a physical examination. These dogs were sedated with 2 mg/kg *i. v.* injection of xylazine hydrochlorure (Rompun-Bayer), followed by symmetrical ventrodorsal and frog-leg view radiographs. The Norberg angle and proportion of the femoral head filling the acetabulum was measured on the x-ray films. Dogs diagnosed with hip dysplasia following clinical and radiological examination and those in which degeneration had not yet begun in the joint, were selected for surgery with their owner's consent.

Patients to have TPO were premedicated with atropine sulphate and xylazine hydrochlorure, after which the operation site was shaved and disinfected. The patient was placed in lateral recumbency on the operation table with the leg to be treated uppermost. Firstly, for the osteotomy of the pubis, the related leg was held at a position of 90° abduction and a 4–5 cm skin incision was made starting from pubis on the inside of the leg between pectineus muscle and gracilis muscle, perpendicular to the median line. The origin of the pectineal muscle was isolated by dissection and after separation, includ-

ing the periosteum, of the part attached to the area of pubis to be osteotomized together with abductor magnus muscle and other soft tissue, a 1–2 cm long piece of bone was removed from the pubis and the area was surgically closed.

For the ischii osteotomy, a 4–6 cm long skin incision was made parallel to tuber ischii, from the lateral aspect to the starting point of arcus ischiadic. A part of the internal obturator muscle connection to tuber ischii was cut and the foramen obturatorium was reached after separating the soft tissue using an osteotome and hands. After sufficient space was achieved, an osteotomy was done on the ischii from the outside towards the inside, parallel to the longitudinal axis of the pelvis. Afterwards, the incision was closed routinely. In 6 of the cases, when the operation was finishing, that is following ilial osteotomy and plating, the cut end of the tuber ischii was fixed using a wire ligature.

The third step was ilial osteotomy and placement of the Canine Osteotomy Plate*. For this, a 10–15 cm skin incision was made between the wing of the ilium to the greater trochanter. Subcutaneous adipose tissue and gluteal fascia was dissected, middle gluteal muscle was revealed and this muscle was separated from the tensor fascia lata muscle.

Starting from the origin of rectus femoris muscle, deep gluteal muscle and in 3 cases middle gluteal muscle were dissected subperiostally and the body of the ilium was reached. The revealed cranial gluteal nerve was protected. Middle gluteal muscle was retracted towards the sacrum and an ilial osteotomy was carried out immediately on the caudal of the sacroiliac joint. During this, it was ensured that ischiadic nerve, passing medially to the ilium, was not damaged.

After osteotomy, according to the degree of dysplasia and the age of the animal, canine pelvic osteotomy plates with a special angle of 40° were placed in 4 iliums, 30° plates in 23 and 20° plates in 4. The plate was first fixed to the caudal portion of the ilium with 3 screws. After this, the ilium was rotated and the same procedure was applied to the cranial portion of the ilium and fixation was completed. Following placement of the plate, in 6 cases the line of osteotomy in the ischii was fixed using cerclage wire. The area was washed with saline solution and muscles, subcutaneous tissues and the skin were sutured and surgically closed. Immediately after the operation, symmetrical VD radiographs were taken. All cases were given antibi-

(* Slocum Enterprises, Eugene, OR)

otics (Sefazolin Sodium) and analgesics (Carprofen) for 5–7 days post-operatively and the skin sutures were removed 8–10 days after surgery.

In order to carry out recovery period check-ups of the dogs which underwent TPO, periodical radiographs were taken. In cases with bilateral dysplasia, the dogs having TPO in both joints, underwent the same procedure within 45–62 days after the first operation.

RESULTS

Following clinical and radiological examinations, hip dysplasia was diagnosed in a total of 22 dogs, of which 5 were unilateral and 17 bilateral. The position of a total of 31 hip joints were changed by carrying out TPO bilaterally in 9 dogs and unilaterally in 13.

Breed distribution of the cases was; 7 German Shepherds, 4 Golden Retrievers, 3 Labrador Retrievers, 2 Anatolian Sheepdogs, 2 Rottweilers, 1 St. Bernard, 1 English Setter, 1 Newfoundland and 1 Napolitan Mastiff. Of the dogs, 17 were male and 5 female. Their ages differed between 5.5–16 months and their body weights were between 19–44 kg.

In most of the cases, physical findings such as difficulty in climbing stairs, a swinging gait, bunny hopping and laxity in the hip joint were observed.

In pre-operative radiographs it was determined that, among the hip joints that had been treated; 16 had severe, 12 moderate and 3 mild dysplasia, the Norberg angle was between 70–92° and that the covering rate of the acetabulum over the femoral head changed between 5–42%. Occurring at the same time as hip dysplasia, medial patellar luxation was seen in 2 of the cases (1 bilateral), panosteitis in the radius, ulna and humerus in 1 case and pes valgus in 1 case. There was noticeable atrophy in the hindleg muscles of the case with the bilateral patellar luxation.

Most of the patients were seen to walk with medium lameness starting from post-operative day 3–5 and that they were bearing weight on the treated leg after day 20–25.

In the radiographs taken immediately after the operation, it was seen that the covering rate of the acetabulum over the femoral head was between 60–100%. Also according to the OFA classification, it was determined that in the post-operative period, 25 hip joints were excellent (75% and over)

and 6 were good (60–75%). In later stage post-operative radiographs (2–6 months), 4 of the 6 cases which had good hip joints were seen to improve to become very good.

Except in 2 of the cases to which TPO was applied, in later period (6–48 months) radiographs degenerative joint disease was not observed in 29 cases. It was determined that, the contact surface between the joint surfaces of the femoral head and the acetabulum had increased and that the dysplastic condition had completely disappeared. The joint laxity (Ortolani and Barden test) noted before the operation disappeared 10–12 weeks after the operation in 23 joints and 13–18 weeks after in 8 joints.

Mineralised callus started to form approximately 1 month later in osteotomized areas and healing was complete within 3–4 months with large callus formation. The bones were seen to gain their normal form with remodeling 7–10 months after the operation.

In cases where cerclage wire was applied to the ischii, it was seen that the callus tissue in the ilium osteotomy line formed faster and that healing was quicker.

In radiographs taken 1 month after the operation; loosening had occurred in the 1st screw in 3 cases, the 2nd and 3rd screws in 1 case and in the 1st, 2nd and 5th screws in 1 case. This however, did not appear to affect the angle given to the acetabulum. In 1 of the cases, a collection occurred at the ischii osteotomy site and this lesion lasted for 9 days. Following the operation, paralysis of sciatic nerve was observed in 3 cases. Two of these cases recovered 10 days later and the remaining case healed 48 days later. In this case however, tarsal hyperextension developed following the recovery of paralysis.

DISCUSSION

The TPO technique has been used for many years, both in cases of dysplasia (Hohn and Janes, 1969; Slocum and Devine, 1986) and traumatic hip luxations (Haburjak *et al.*, 2001), in order to provide stability and congruency between the acetabulum and the femoral head. On the other hand, the ideal method to be used in the treatment of hip dysplasia has not yet been determined. In a study comparing the late period results of conservative, excision arthroplasty and TPO treatments in hip dysplasia,

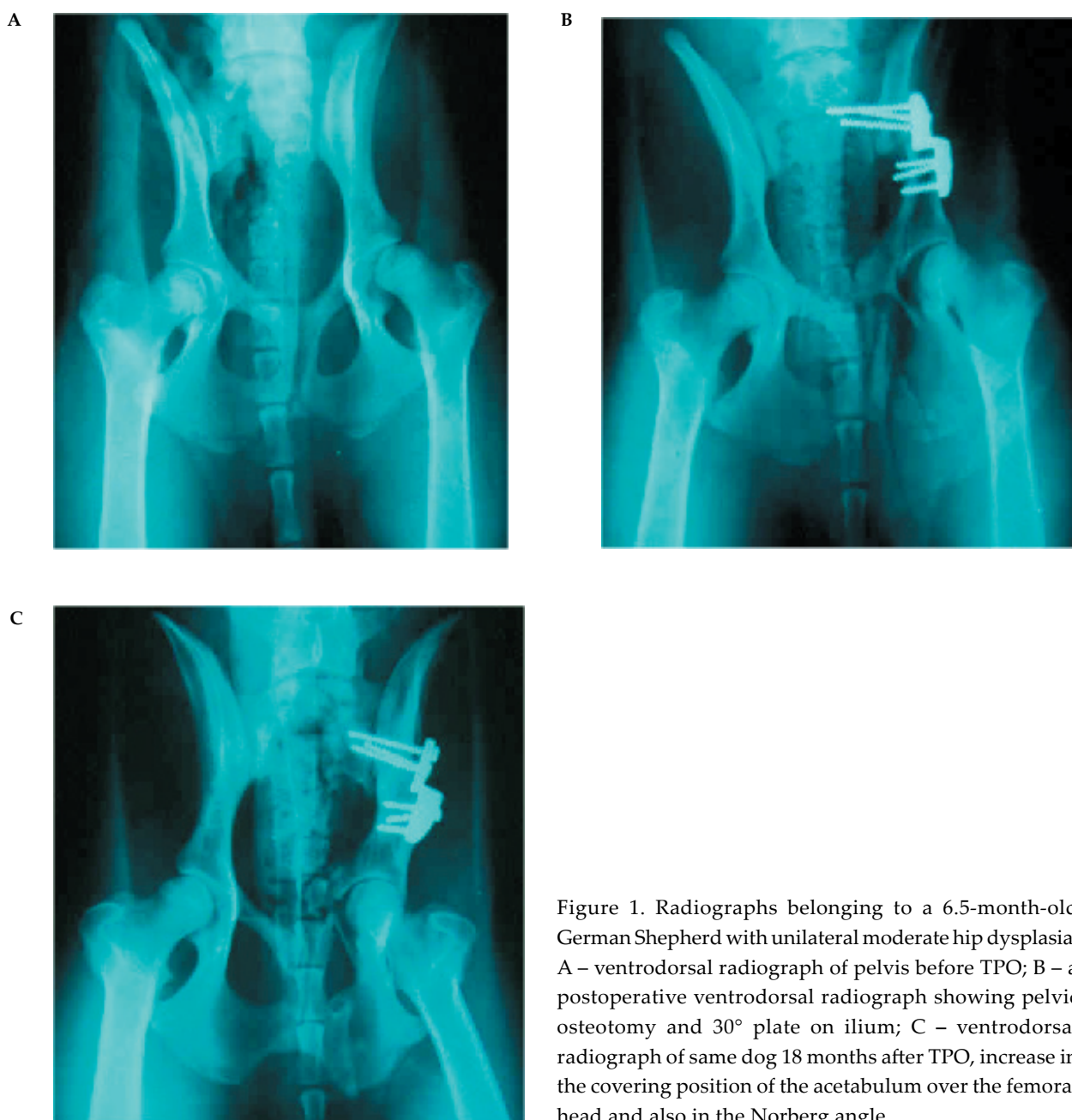


Figure 1. Radiographs belonging to a 6.5-month-old German Shepherd with unilateral moderate hip dysplasia. A – ventrodorsal radiograph of pelvis before TPO; B – a postoperative ventrodorsal radiograph showing pelvic osteotomy and 30° plate on ilium; C – ventrodorsal radiograph of same dog 18 months after TPO, increase in the covering position of the acetabulum over the femoral head and also in the Norberg angle

Plante *et al.* (1997) reported that they had achieved the best results with TPO. In this study, the fact that 29 of the 31 hip joints which were treated with TPO, had trouble-free recovery supports this view.

Although the disease has been reported to be seen more frequently in bitches (Swenson *et al.*, 1997), it was interesting that most of the dogs to which TPO was applied were male (77%). All of the cases comprised of dog breeds reported to be predisposed to the disease (Corley, 1992; Lust, 1997).

Similar to the reports (Rasmussen *et al.* 1998; Tano *et al.*, 1998), it was seen in the post-operative

radiographs of the cases, that there was a reasonable increase in the covering position of the acetabulum over the femoral head and also in the Norberg angle (Figure 1). The fact that, the covering rate of the acetabulum over the femoral head was very good in 25 cases, good in 6 cases according to the classification done by OFA (Henry, 1992; Plante *et al.*, 1997) and the cessation or lack of degenerative disorders, confirms the view of Plante *et al.* (1997) stating that TPO is a reliable method in the treatment of hip dysplasia.

In the later period radiographs of the 6 cases with a good covering rate of the acetabulum over the femoral head, when 4 were seen to have developed a better covering rate, it can be said that in time the congruency within the joint will gradually improve.

Partial narrowing was observed in the pelvic canals of the patients to which bilateral TPO was applied. This narrowing was most in the cases which were given 40° plates and least in those given 20° plates. However, this condition did not cause any problems. The patient owners were informed that dysplasia is a hereditary disease and that their dogs should be neutered.

Of the 16 hip joints which had severe dysplasia, 40° plates were applied to 4 and 30° plates were applied to 12. It was seen that 30° plates provided sufficient axial rotation in severe and moderate dysplasia (Figure 1) and similarly, 20° plates in mild dysplasia. In cases with 40° plates, excessive callus and late union was observed related to excessive rotation. We therefore completely support the opinion of Manley (1993), stressing that it is unnecessary to use 40° plates.

While Johnson *et al.* (1998), have reported that the degeneration in the joint continued even after TPO, Wallace and Olmstead (1995) state the opposite. The fact that, with the exception of 2 of our cases, we did not encounter such complications, is parallel to the view of Wallace and Olmstead (1995). The degeneration in these 2 cases was present before the operation and stopped progressing after surgery.

It was reported that, 7 of the male dogs had difficulty in lifting their hindlegs (abduction) during urination. We suspect this was due to the contact between the femoral head and the dorsal rim of the acetabulum during abduction (Slocum and Devine, 1986) or the excessive straining of the pectineal muscle.

Even after the treatment of hip dysplasia using both intertrochanteric osteotomy (Braden and Prieur, 1992) and the lengthening operation of the femoral head, the possible degeneration inside the joint cannot be avoided. This is why we think that, the method of choice for the treatment of hip dysplasia should provide an angle for the acetabulum, rather than the femur, and so prevent or stop degeneration forming within the joint.

While Simmons *et al.* (2001), have reported that using a hemicerclage wire to secure ischial osteotomy decreases the frequency of screw migration, Remedios and Fries (1993) reported that, application of cerclage wire to the ischii and ilium osteotomy

lines did not have any effect on screw loosening. In the screw loosening that occurred in our cases, we think that excessive movement of the animals played an important role and that rather than applying cerclage wire to the ischii, confinement of the patients to a restricted area for at least 20 days would combat this problem to a certain degree. We observed that, the screw loosening occurring in this study did not cause any problems in the angle given to the acetabulum.

It was interesting that, in 2 of the 3 cases in which paralysis of sciatic nerve developed, 40° plates were used and the middle gluteal muscle had been subperostally dissected.

As a result, we can state that, in hip dysplasia, which is a hereditary disease, a reasonably successful clinical recovery was achieved in young dogs, with such an operation carried out before degenerative disorders began within the joint and that there was no joint degeneration in the late period check-ups.

REFERENCES

- Alexander J.W. (1992): The pathogenesis of canine hip dysplasia. *Vet. Clin. N. Am.-Small*, 22, 503–511.
- Braden T.D., Prieur W.D. (1992): Three-plane intertrochanteric osteotomy for treatment of early stage hip dysplasia. *Vet. Clin. N. Am.-Small*, 22, 623–643.
- Cardinet G.H., Kass P.H., Wallace L.J., Guffy M.M. (1997): Association between pelvic muscle mass and canine hip dysplasia. *J. Am. Vet. Med. Assoc.*, 210, 1466–1473.
- Corley E.A. (1992): Role of the orthopedic foundation for animals in the control of canine hip dysplasia. *Vet. Clin. N. Am.-Small*, 22, 579–593.
- Dejardin L.M., Perry R.L., Arnoczky S.P. (1998): The effect of triple pelvic osteotomy on the articular contact area of the hip joint in dysplastic dogs: An *in vitro* experimental study. *Vet. Surg.*, 27, 194–202.
- Denny H.R., Butterworth S. (2000): The hip. In: *A Guide to Canine and Feline Orthopaedic Surgery*. 4 Ed. Blackwell Science, London. 455–494.
- Haburjak J.J., Lenehan T.M., Harari J. *et al.* (2001): Treatment of traumatic coxofemoral luxation with triple pelvic osteotomy in 19 dogs (1987–1999). *Vet. Comp. Orthop. Traumatol.*, 14, 69–77.
- Henry G.A. (1992): Radiographic development of canine hip dysplasia. *Vet. Clin. N. Am.-Small*, 22, 559–578.
- Hohn R.B., Janes J.M. (1969): Pelvic osteotomy in the treatment of canine hip dysplasia. *Clin. Orthop. Rel. Res.*, 62, 70–78.

- Johnson A.L., Smith C.W., Pijanowski G.J., Hungerford L.L. (1998): Triple pelvic osteotomy: Effect on limb function and progression of degenerative joint disease. *J. Am. Anim. Hosp. Assoc.*, 34, 260–264.
- Lust G. (1993): Other orthopedic diseases. In: Slatter D. (ed.): *Textbook of Small Animal Surgery*. 2 ed. Saunders Co., Philadelphia. 1938–1944.
- Lust G. (1997): An Overview of the Pathogenesis of canine hip dysplasia. *J. Am. Vet. Med. Assoc.*, 210, 1443–1445.
- Manley P.A. (1993): The hip joint. In: Slatter D. (ed.): *Textbook of Small Animal Surgery*. 2 ed. W.B. Saunders Co., Philadelphia. 1786–1805.
- Piermatei D.L., Flo G.L. (1997): Hip Dysplasia. In: Saunders W.B. (ed.): *Brinker, Piermatei and Flo's Handbook of Small Animal Orthopedics and Fracture Repair*. Co. Philadelphia. 433–465.
- Plante J., Dupuis J., Beauregard G., Bonneau N.H., Breton L. (1997): Long-term results of conservative treatment, excision arthroplasty and triple pelvic osteotomy for the treatment of hip dysplasia in the immature dog. 1. Radiographic and physical results. *Vet. Comp. Orthop. Traumatol.*, 10, 130–135.
- Rasmussen L.M., Kramek B.A., Lipowitz A.J. (1998): Preoperative variables affecting long-term outcome of triple pelvic osteotomy for treatment of naturally developing hip dysplasia in dogs. *J. Am. Vet. Med. Assoc.*, 213, 80–85.
- Remedios A.M., Fries C.L. (1993): Implant complication in 20 triple pelvic osteotomies. *Vet. Comp. Orthop. Traumatol.*, 6, 202–207.
- Simmons S., Johnson A.L., Schaeffer D.J. (2001): Risk factors for screw migration after triple pelvic osteotomy. *J. Am. Anim. Hosp. Assoc.*, 37, 269–273.
- Slocum B., Devine T. (1986): Pelvic osteotomy technique for axial rotation of the acetabular segment in dogs. *J. Am. Anim. Hosp. Assoc.*, 22, 331–338.
- Slocum B., Slocum D.T. (1992): Pelvic osteotomy for axial rotation of the acetabular segment in dogs with hip dysplasia. *Vet. Clin. N. Am.-Small*, 22, 645–682.
- Smith G.K. (1997): Advances in diagnosing canine hip dysplasia. *J. Am. Vet. Med. Assoc.*, 210, 1451–1457.
- Smith G.K., Darryl N.B., Gregor T.P. (1990): New concepts of coxofemoral joint stability and the development of a clinical stress-radiographic method for quantitating hip joint laxity in the dog. *J. Am. Vet. Med. Assoc.*, 196, 60–70.
- Smith G.K., Hill C.M., Gregor T.P., Olson K. (1998): Reliability of the hip distraction index in two-month-old German Shepherd dogs. *J. Am. Vet. Med. Assoc.*, 212, 1560–1563.
- Swenson L., Audell L., Hedhammar A. (1997): Prevalence and inheritance of and selection for hip dysplasia in seven breeds of dogs in Sweden and benefit: Cost analysis of a screening and control program. *J. Am. Vet. Med. Assoc.*, 210, 207–214.
- Tano C.A., Cockshutt J.R., Dobson H. *et al.* (1998): Force plate analysis of dogs with bilateral hip dysplasia treated with a unilateral triple pelvic osteotomy: A long-term review of cases. *Vet. Comp. Orthop. Traumatol.*, 11, 85–93.
- Tomlinson J.L., Johnson J.C. (2000): Quantification of measurement of femoral head coverage and Norberg angle within and among four breeds of dogs. *Am. J. Vet. Res.*, 61, 1492–1500.
- Wallace L.J., Olmstead M.L. (1995): Disabling conditions of canine coxofemoral joint. In: Olmstead M.L. (ed.): *Small Animal Orthopaedics*. Mosby, Philadelphia. 361–393.

Received: 02–10–20

Accepted after corrections: 03–02–27

Corresponding Author

Kemal Altunatmaz, Surgery Department, Faculty of Veterinary Medicine, Istanbul University, 34851-Avcilar, Istanbul, Turkey
Tel. +90 212 591 69 84, fax +90 212 591 69 76, e-mail: altunatmaz@hotmail.com
